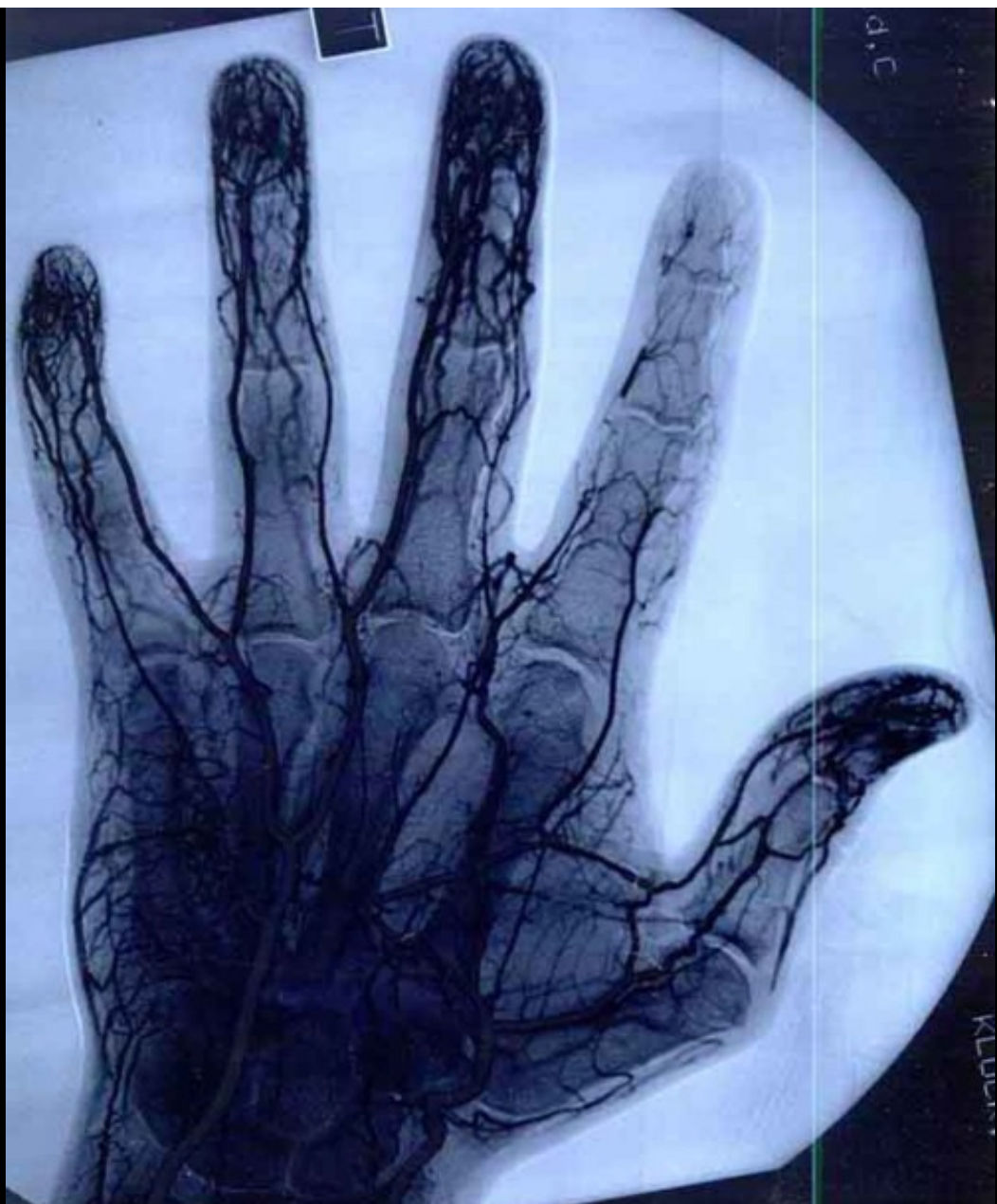



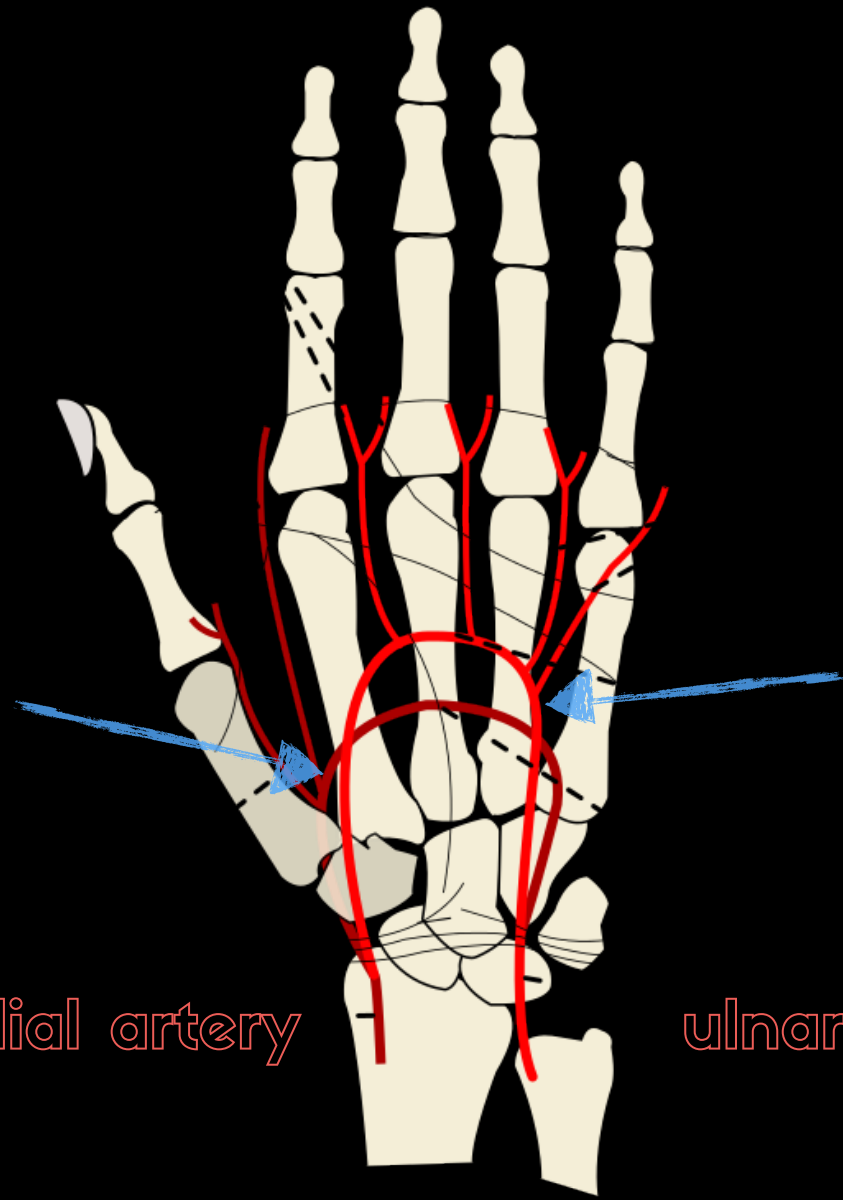
**STAY ON TARGET**

the blood

the vessels  
the thumb



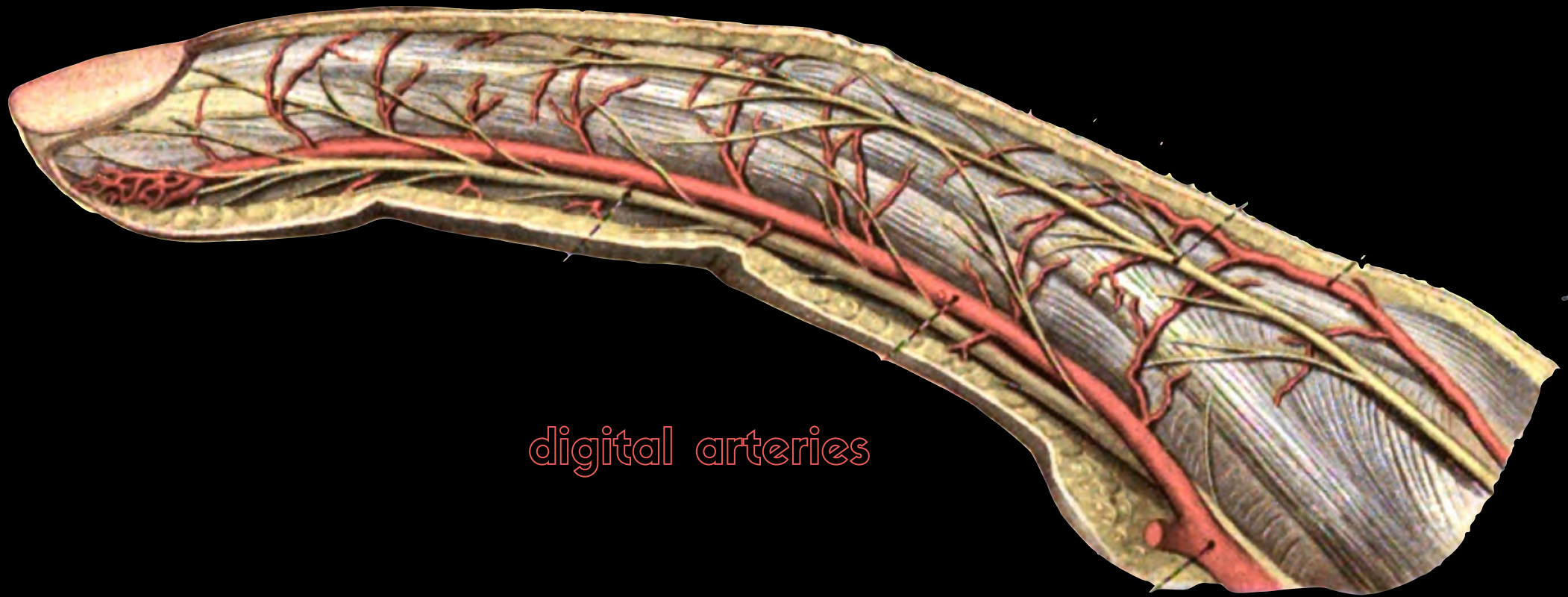
deep arch  
[mainly radial]



superficial arch  
[mainly ulnar]

radial artery

ulnar artery




digital arteries





the thumb

flexion




extension






**adduction**

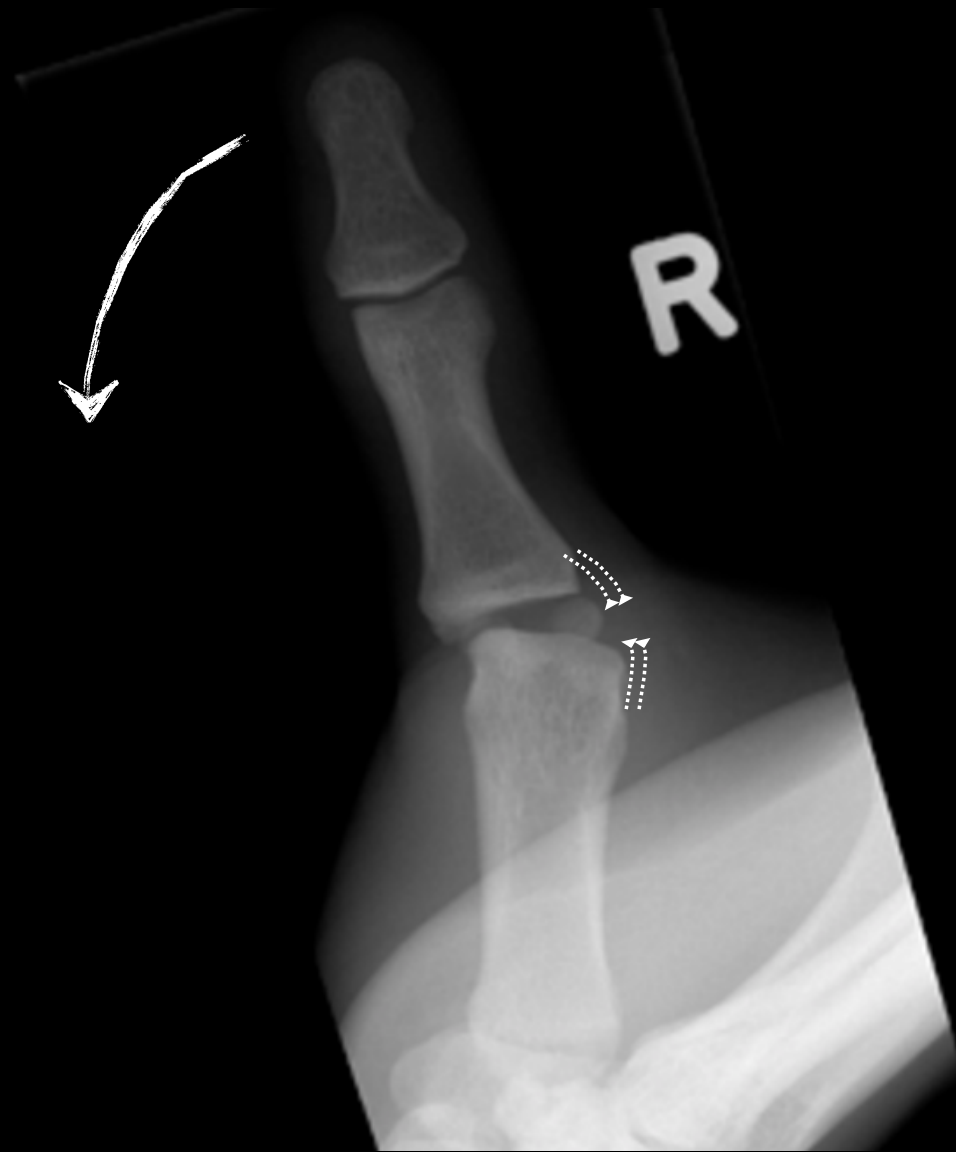

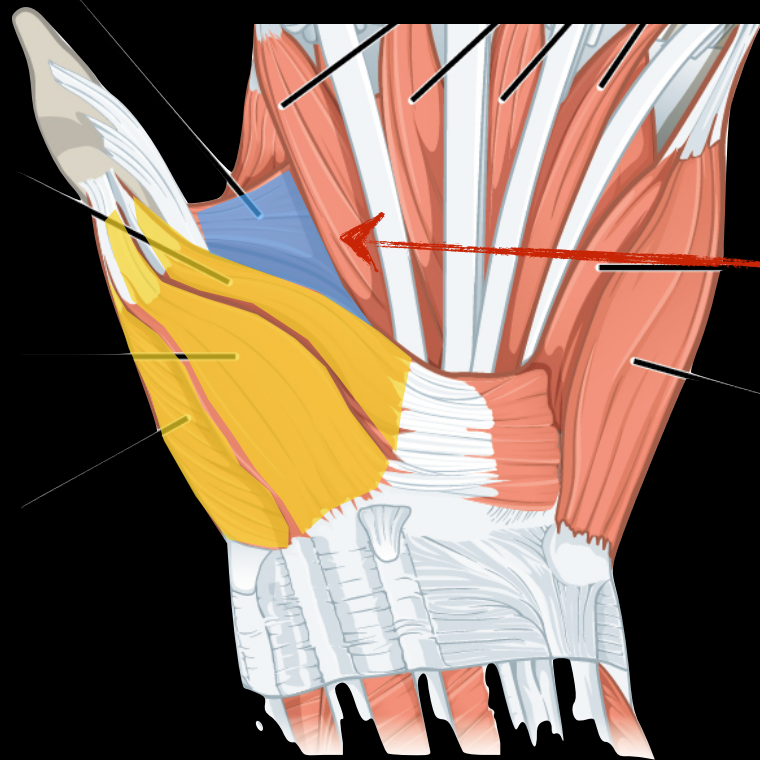
**abduction**



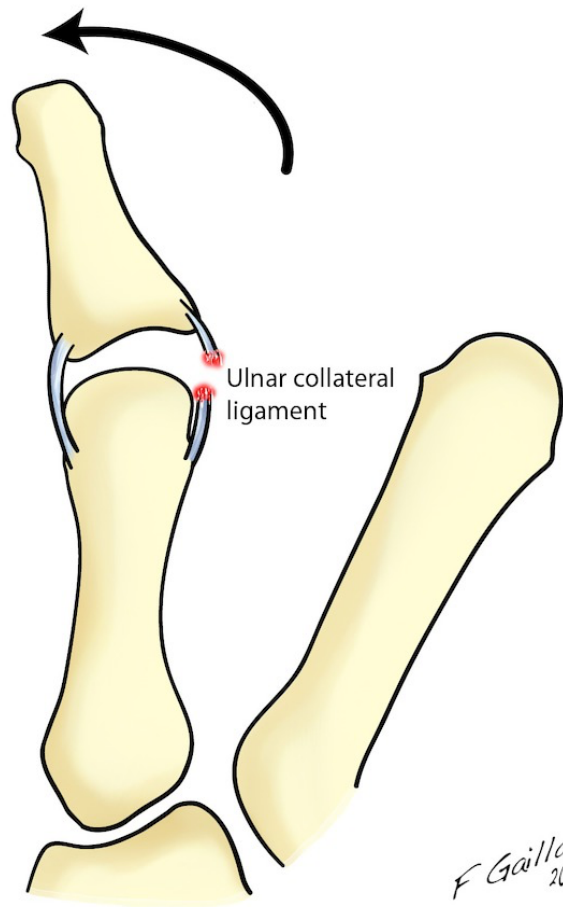
ulnar collateral  
ligament





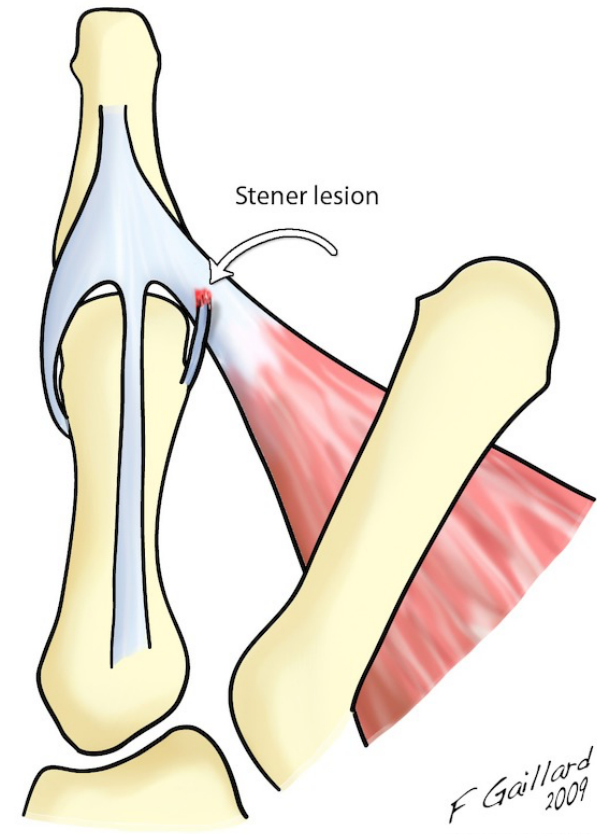


adductor pollicis



*F Gaillard  
2009*

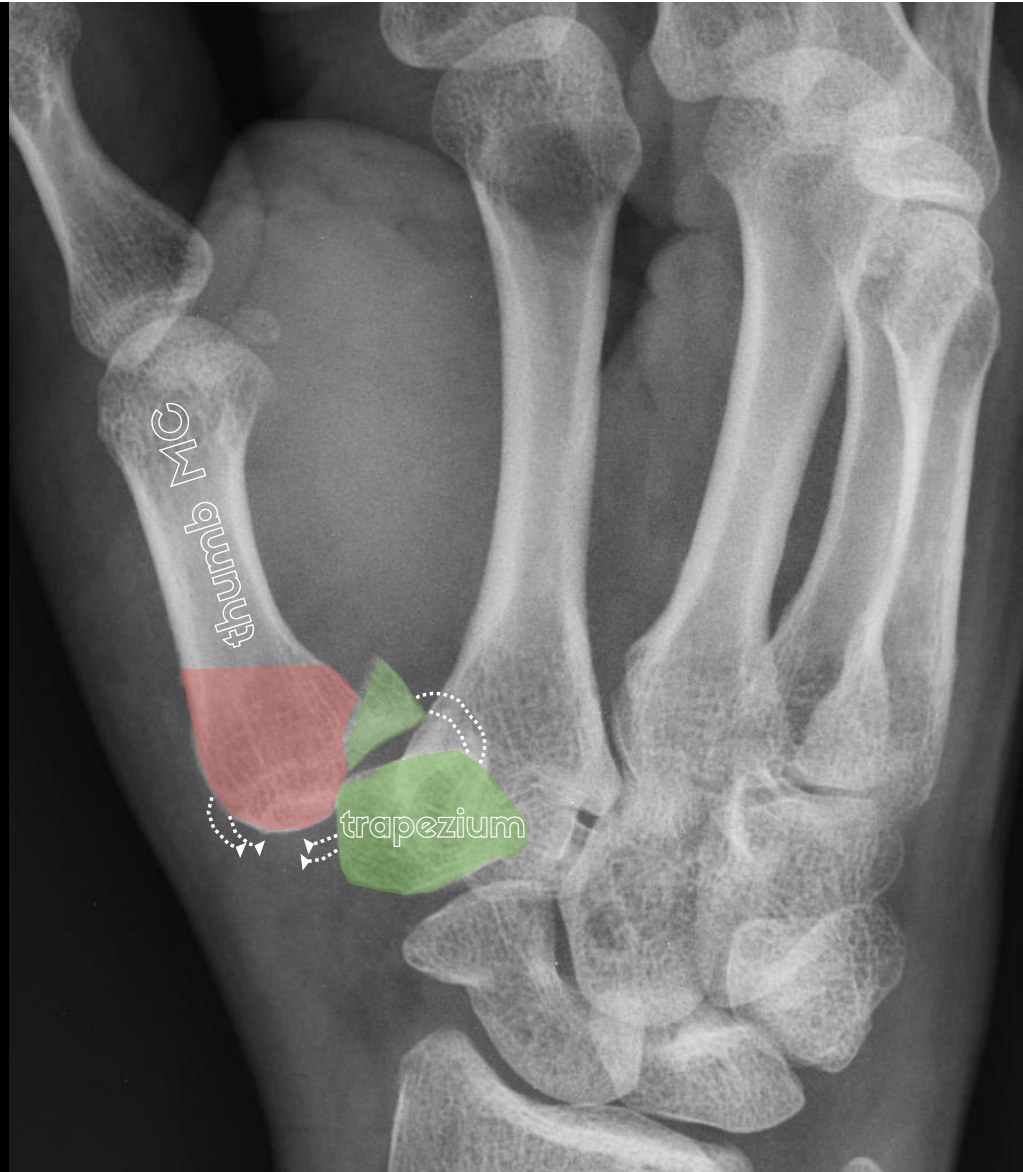
Radiopaedia.org CC-NC-SA-BY



*F Gaillard  
2009*

Radiopaedia.org CC-NC-SA-BY

Case courtesy of A.Prof Frank Gaillard, Radiopaedia.org, rID: 7641

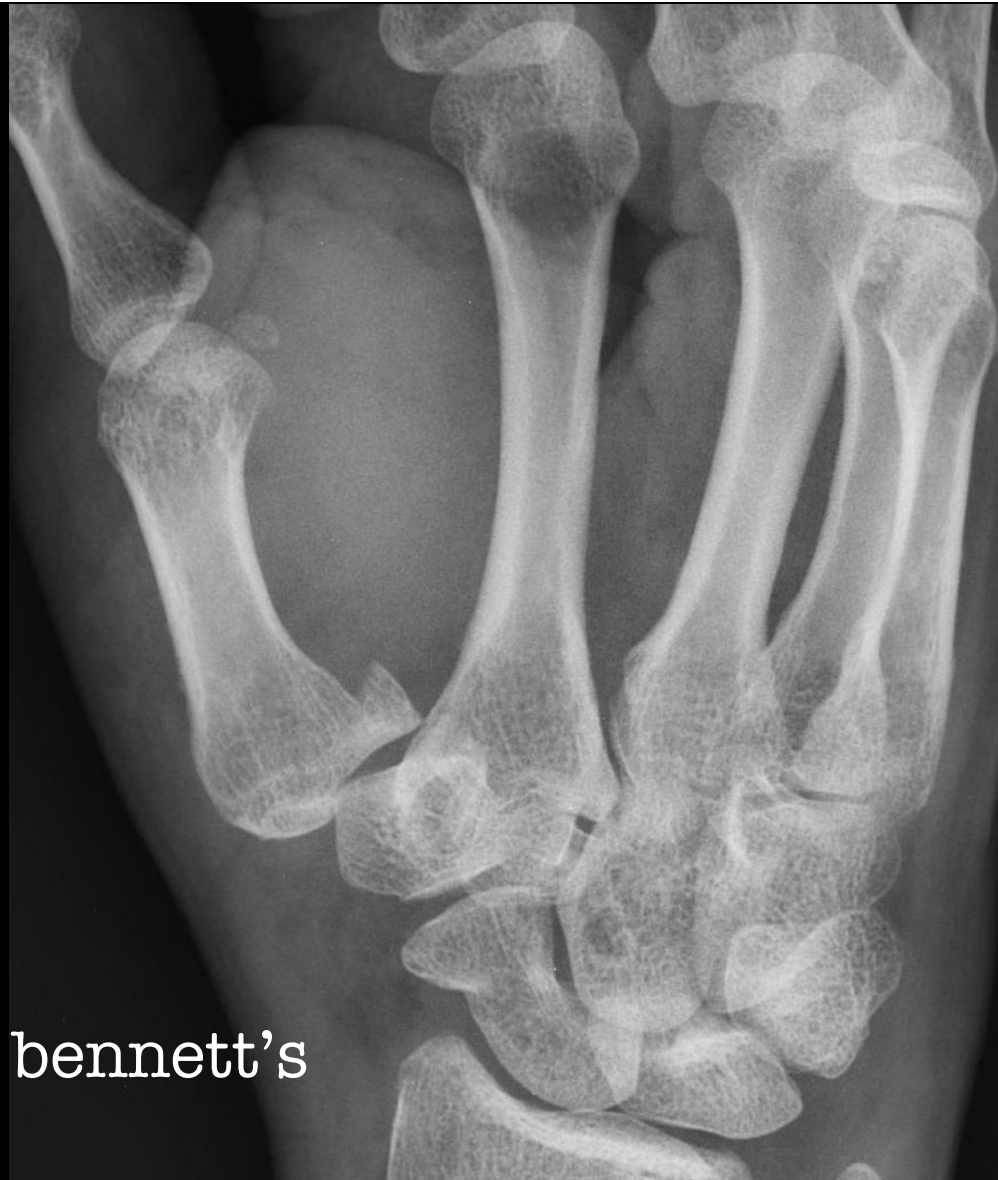

Case courtesy of Dr Maulik S Patel, Radiopaedia.org, rID: 17745

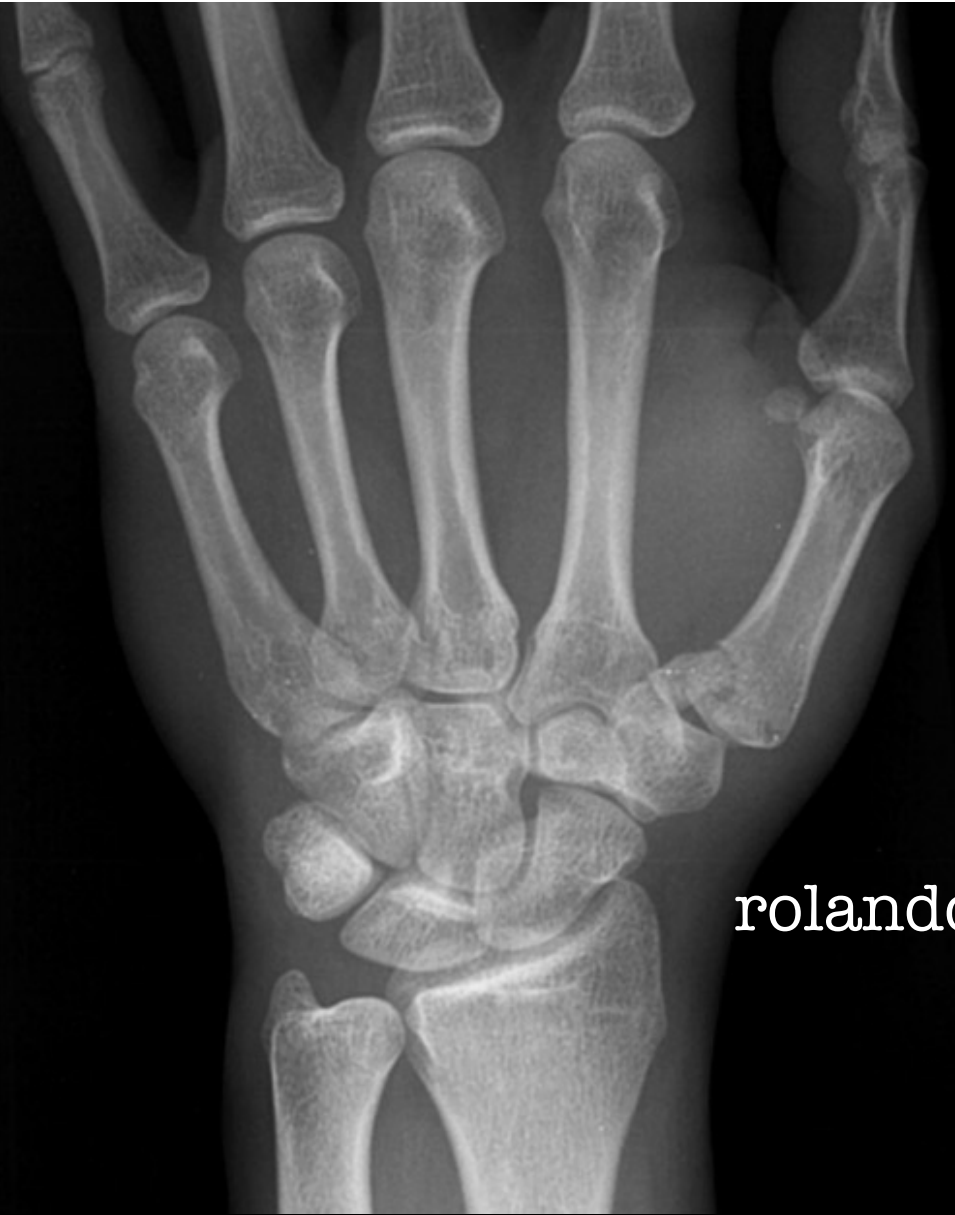

Case courtesy of A.Prof Frank Gaillard, Radiopaedia.org, rID: 35855






bennett's



rolando







**ITS OVER. GO HOME!**