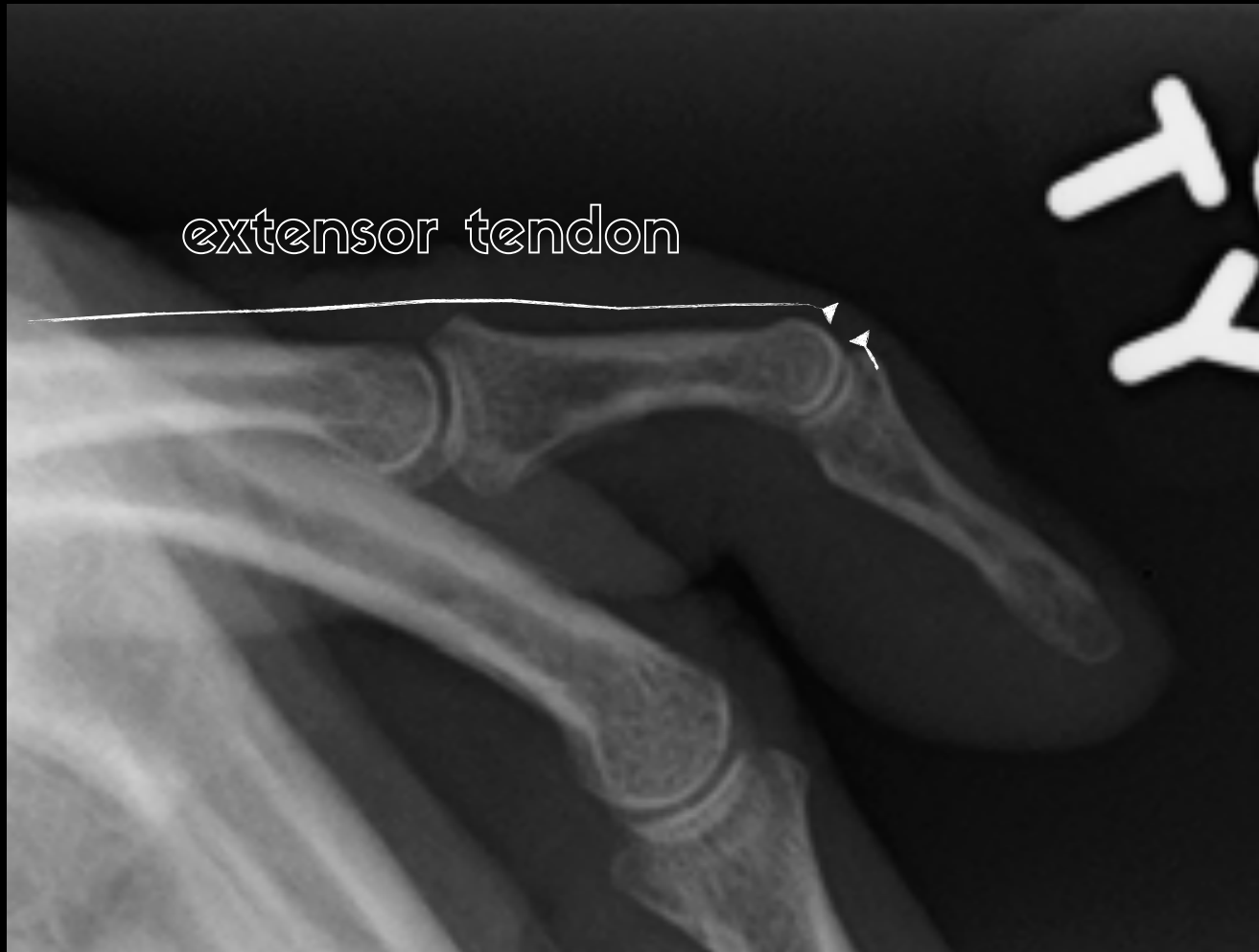

the extensor
tendons

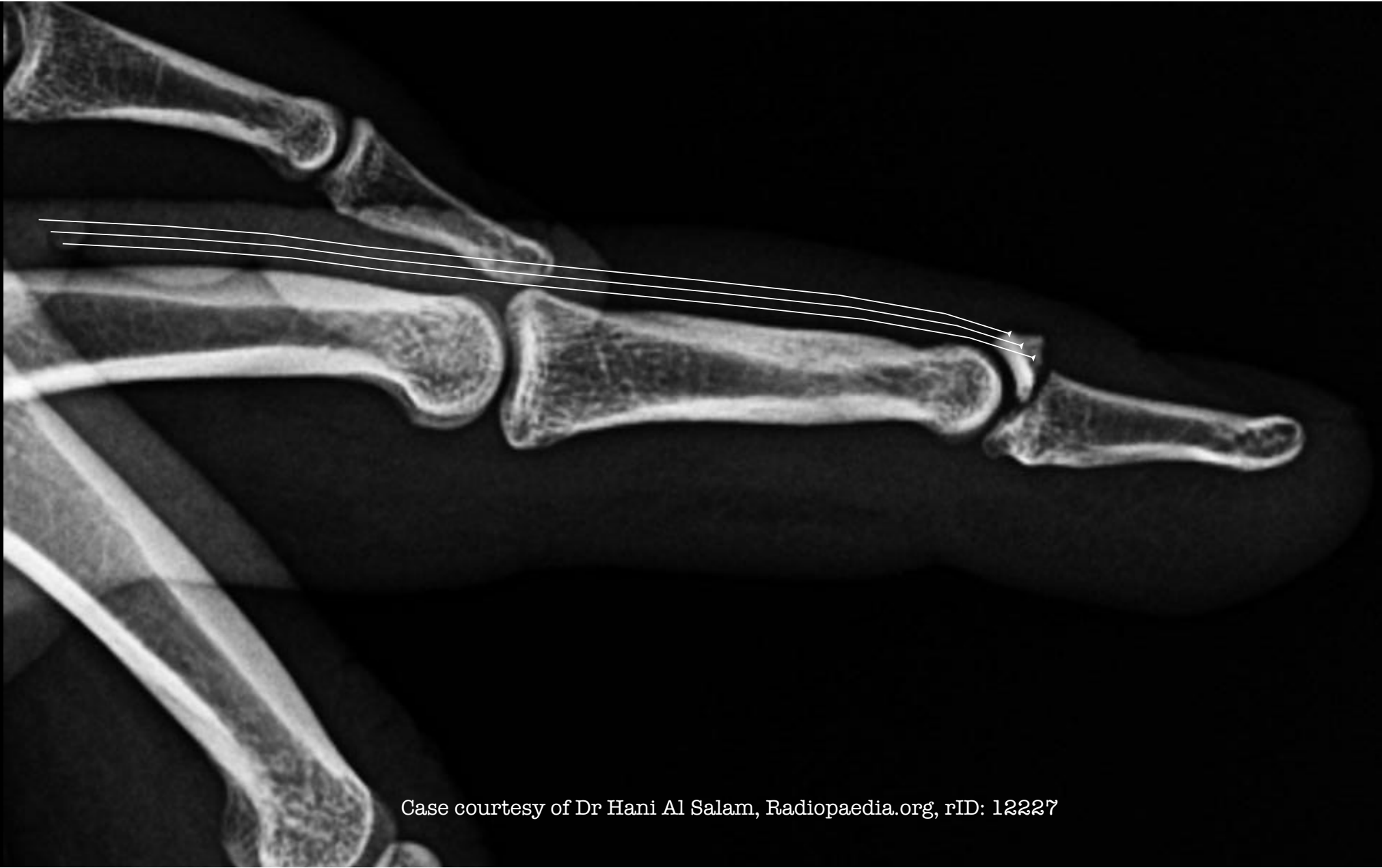

mallet finger

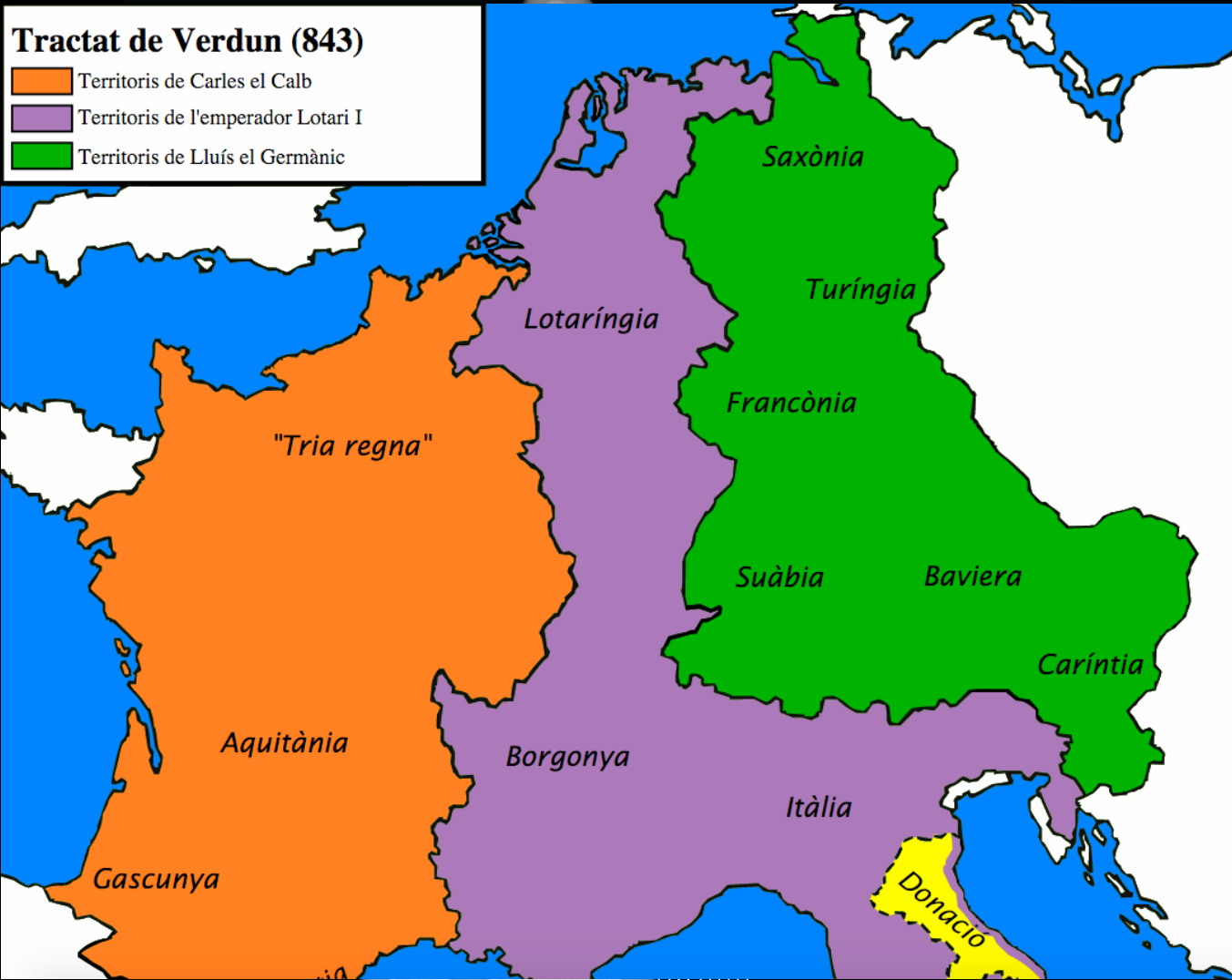
image credit: James Heilman, MD on wikimedia commons



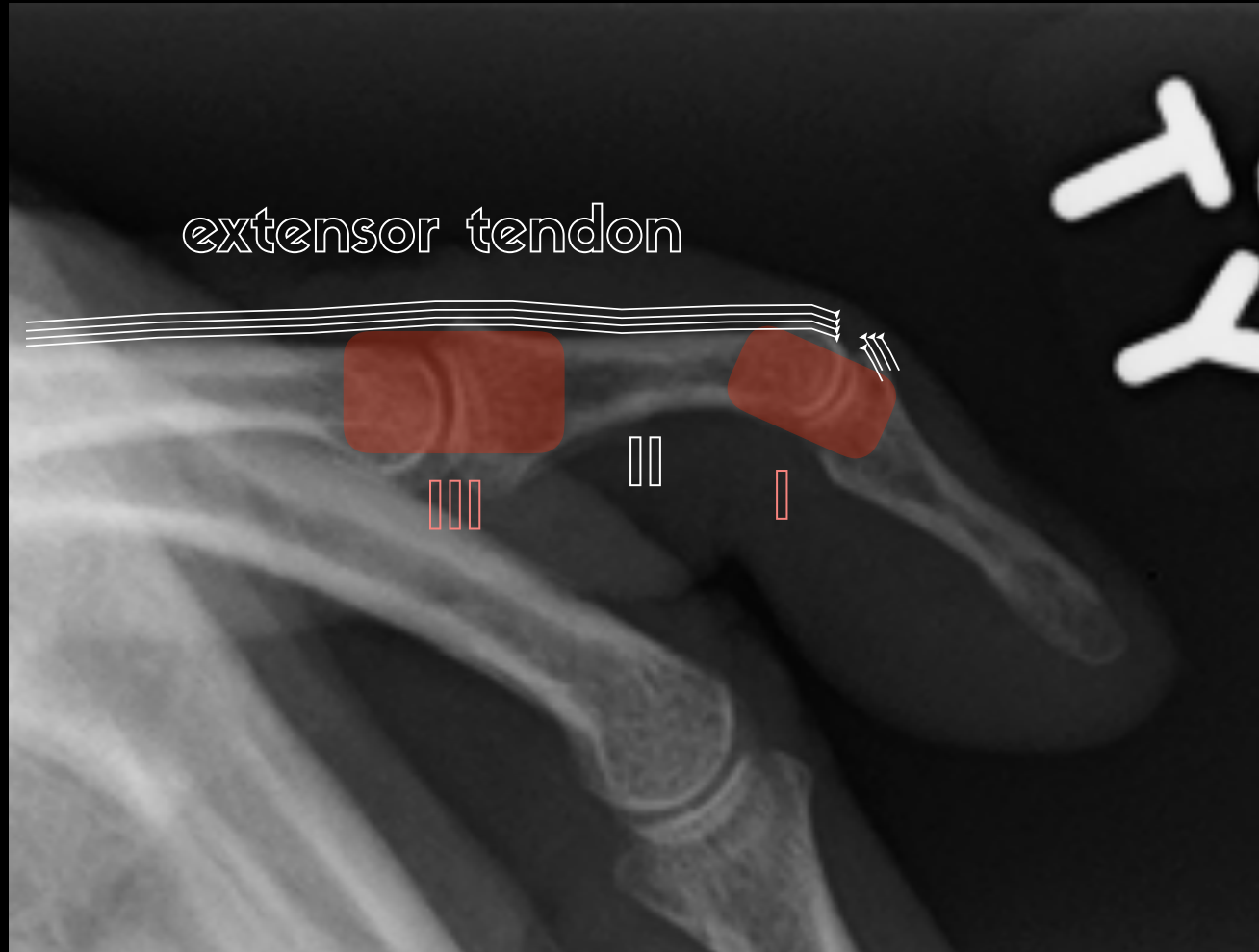
*Frostfell
races*



Case courtesy of Dr Hani Al Salam, Radiopaedia.org, rID: 12227



extensor tendon



X

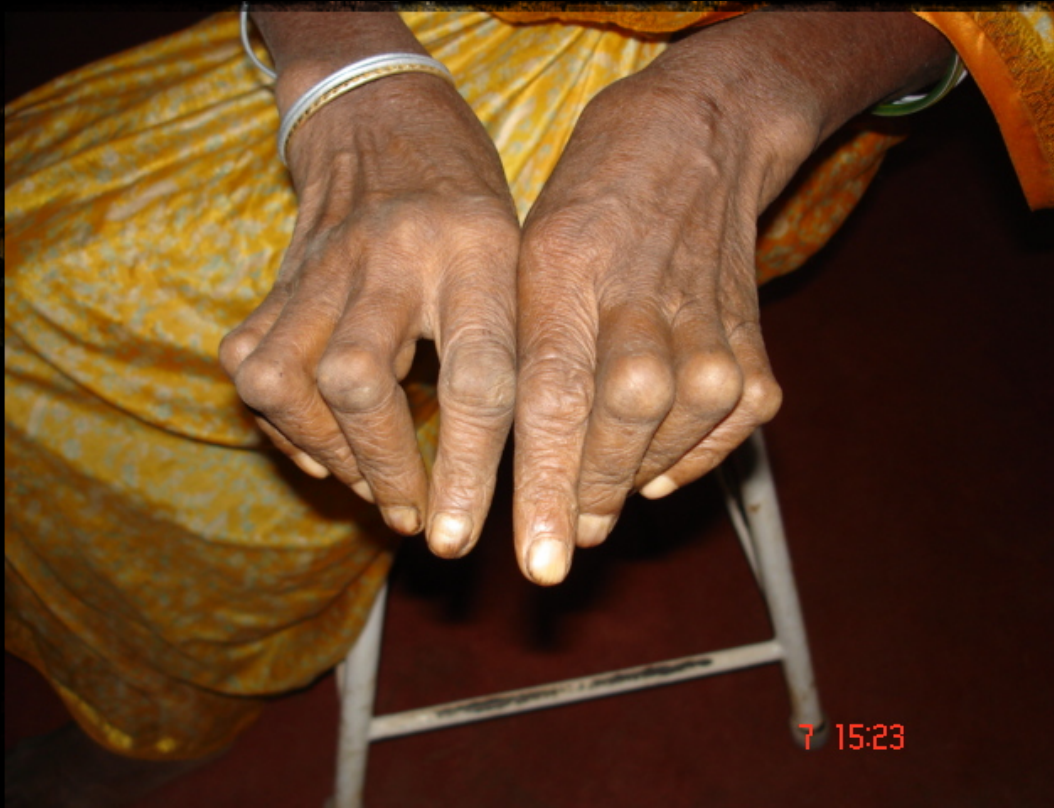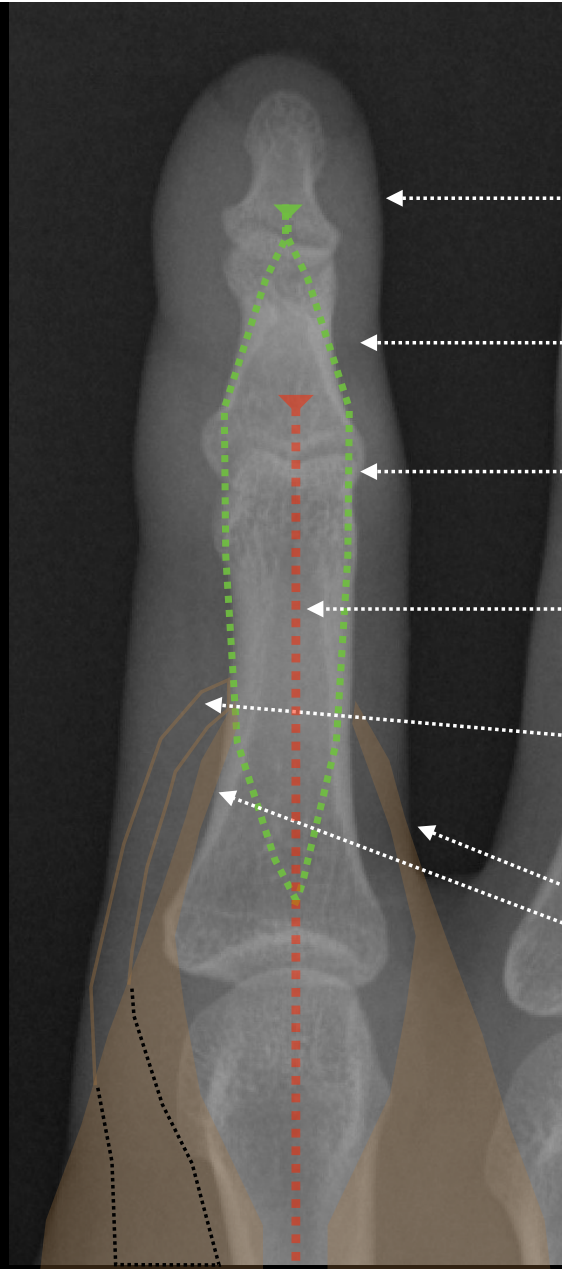


image credit: Prashanthns wikimedia commons
https://en.wikipedia.org/wiki/File:RA_hand_deformity.JPG

✓

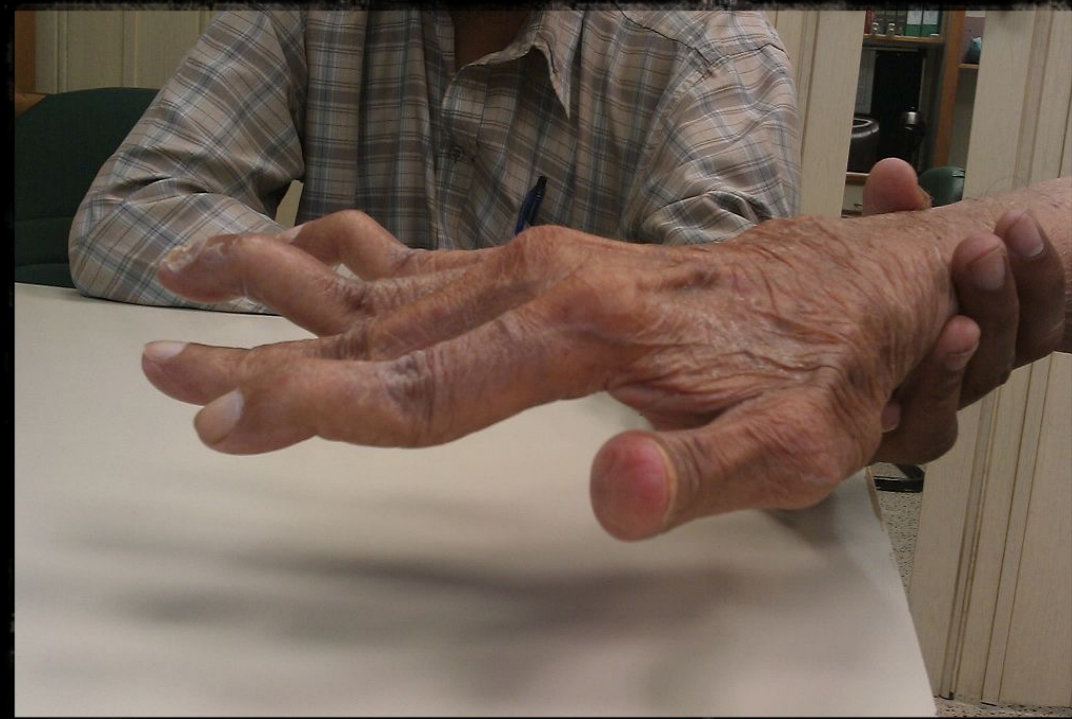

image credit: Phoenix119 wikimedia commons



DP insertion

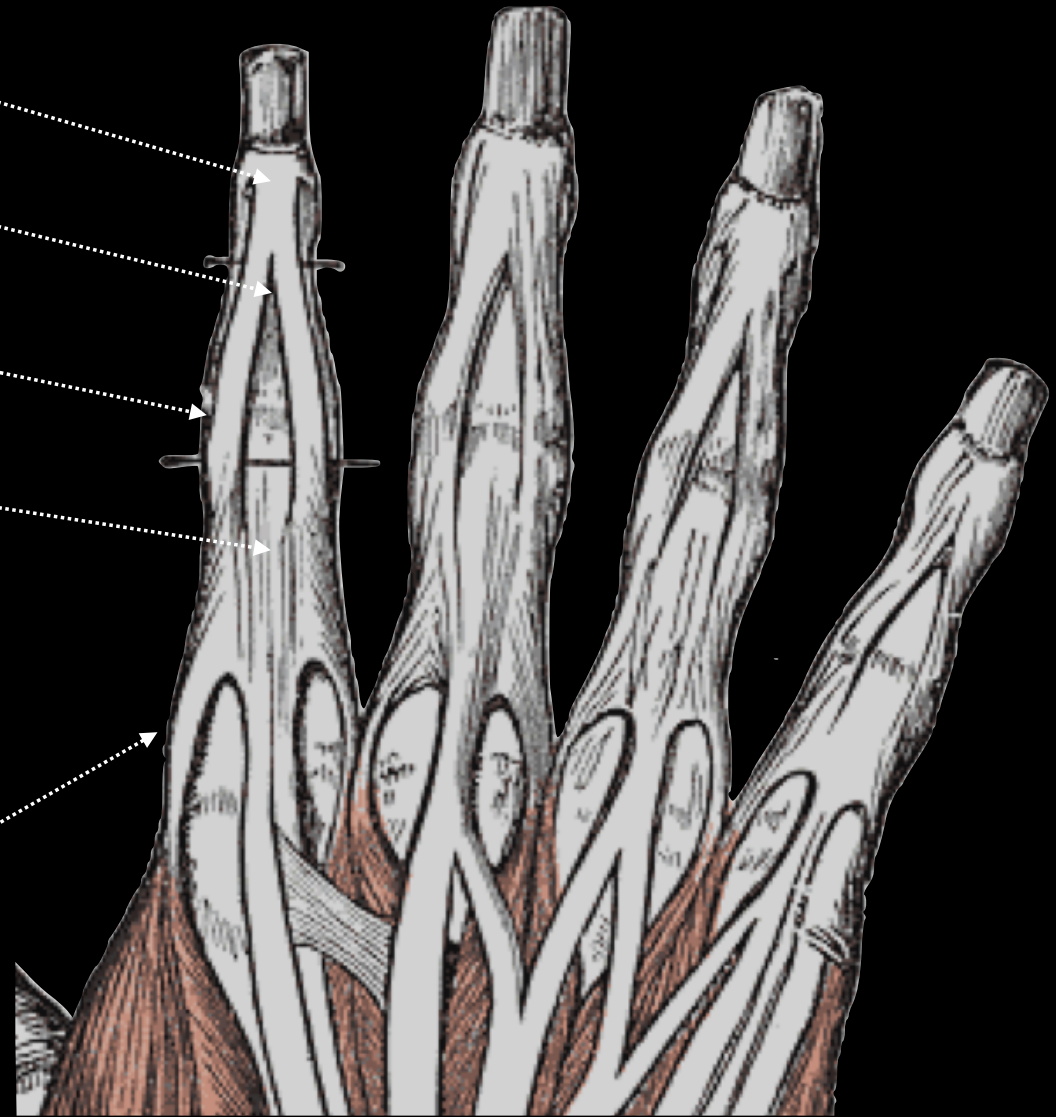
MP insertion

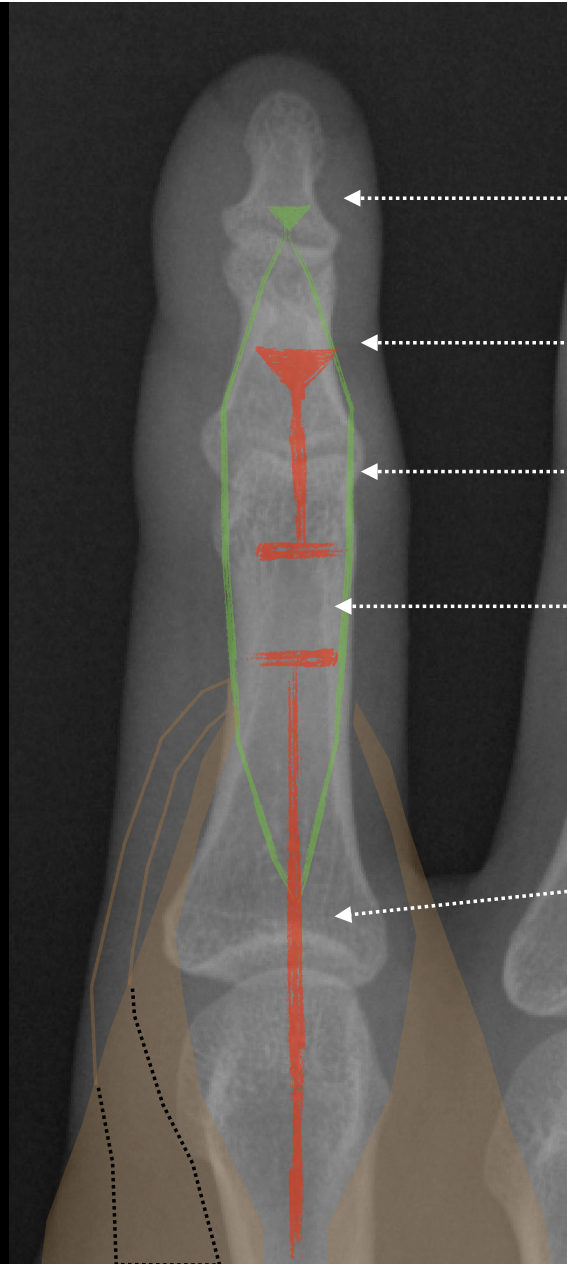
lateral bands

central slip

lumbrical

interossei





DP insertion

MP insertion

lateral bands remain intact

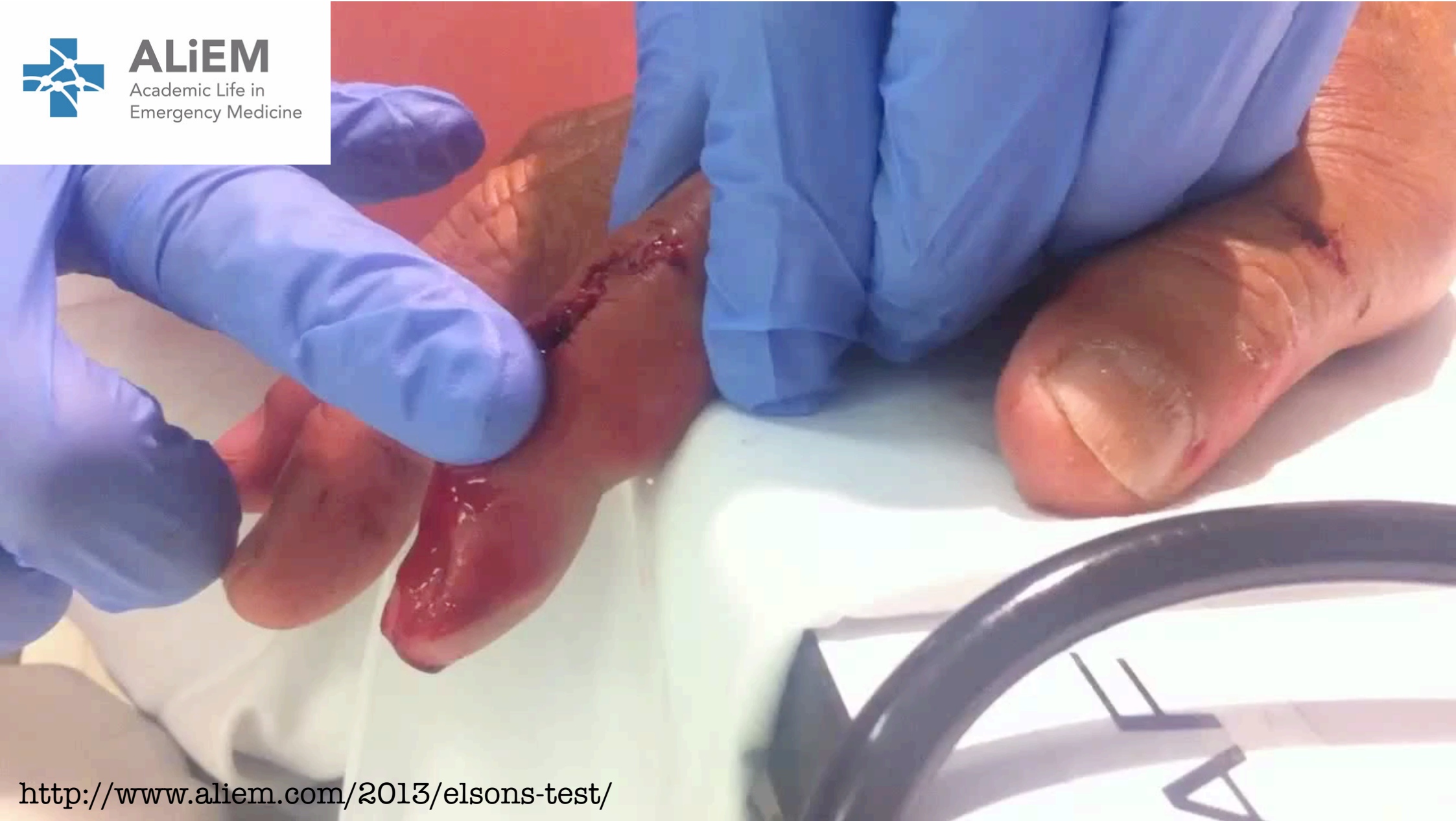ruptured central slip

central slip



ALiEM

Academic Life in
Emergency Medicine



<http://www.aliem.com/2013/elsons-test/>

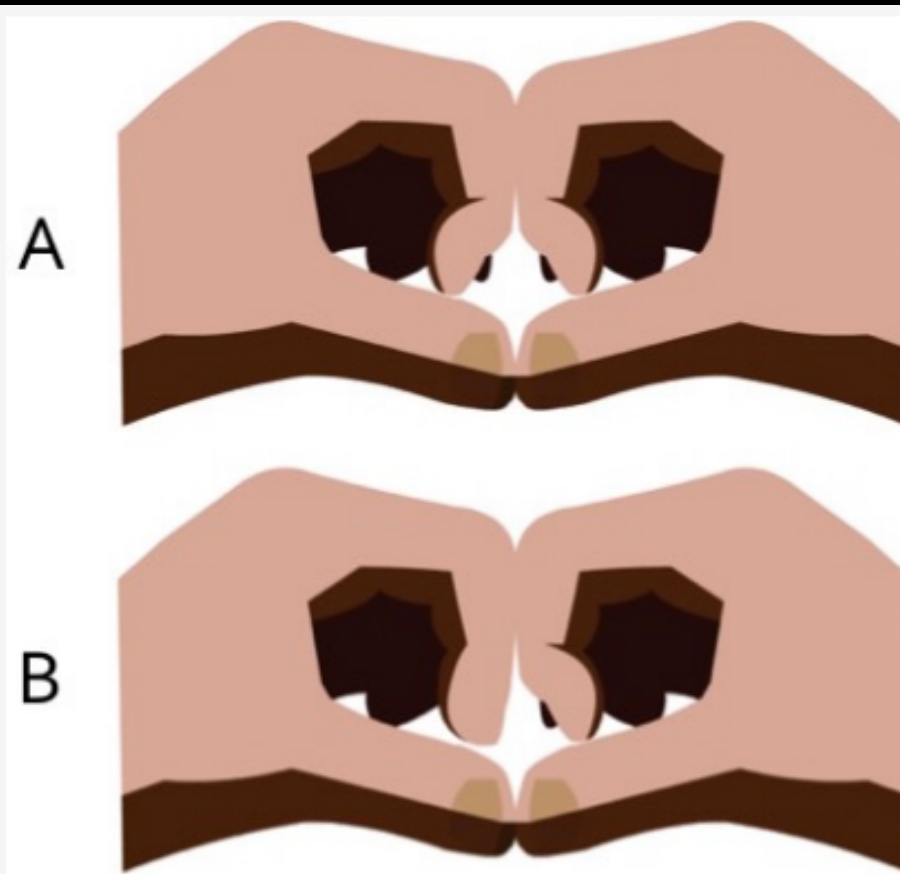


Figure 3: The modified Elson's test. A) Uninjured fingers show a symmetric inability to straighten the distal interphalangeal joint when the middle interphalangeal joints are flush against each other. B) In a central slip injury, the distal interphalangeal joint is pathologically straightened, which is seen in the left hand in this example. (*Illustration by David Ting*)

juncturae tendinum

