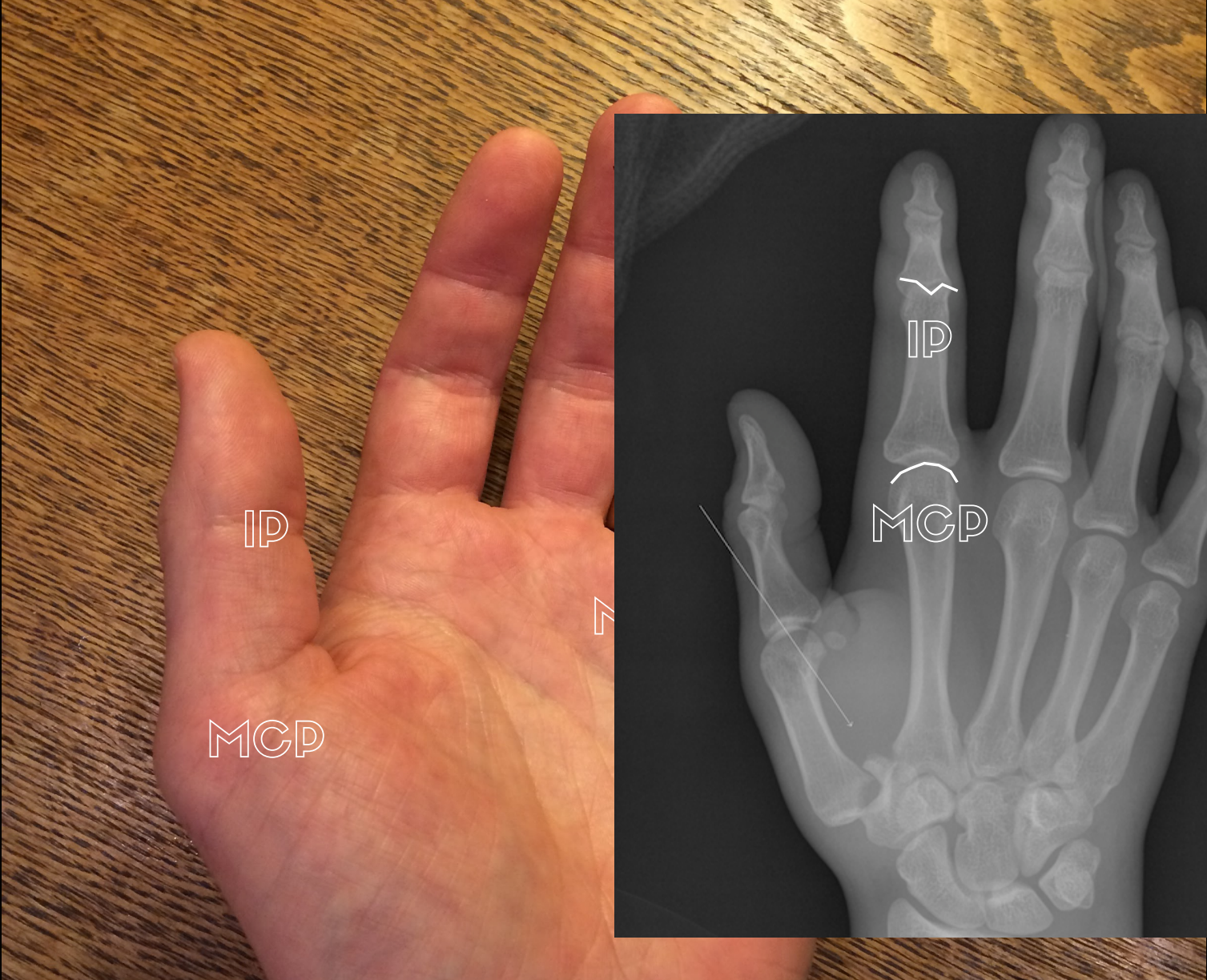
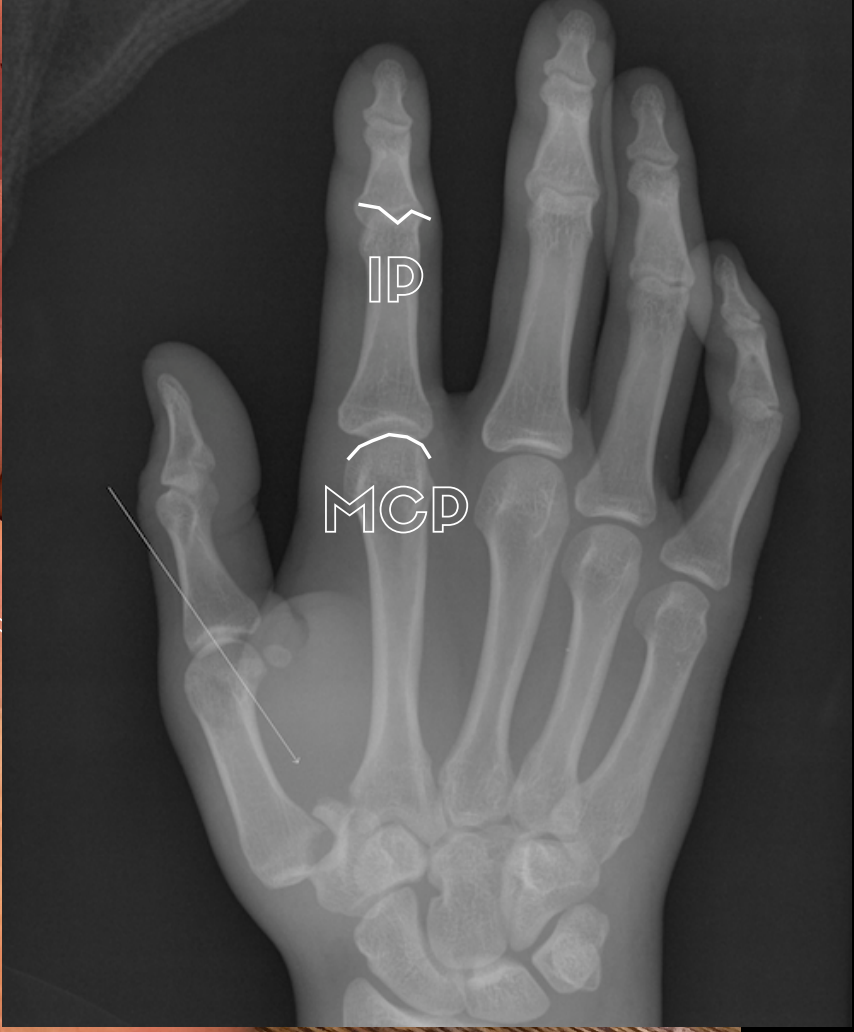

the fingers



IP

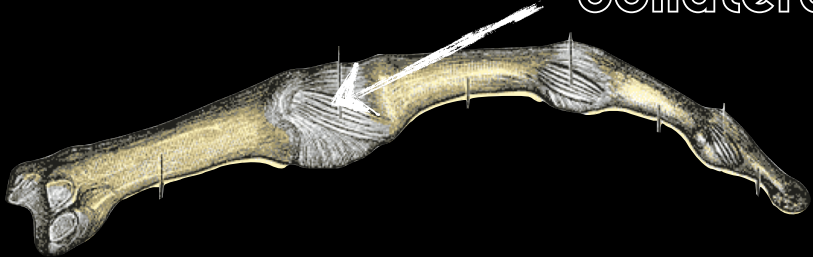
MCP



IP

MCP

collateral ligament



extension



flexion



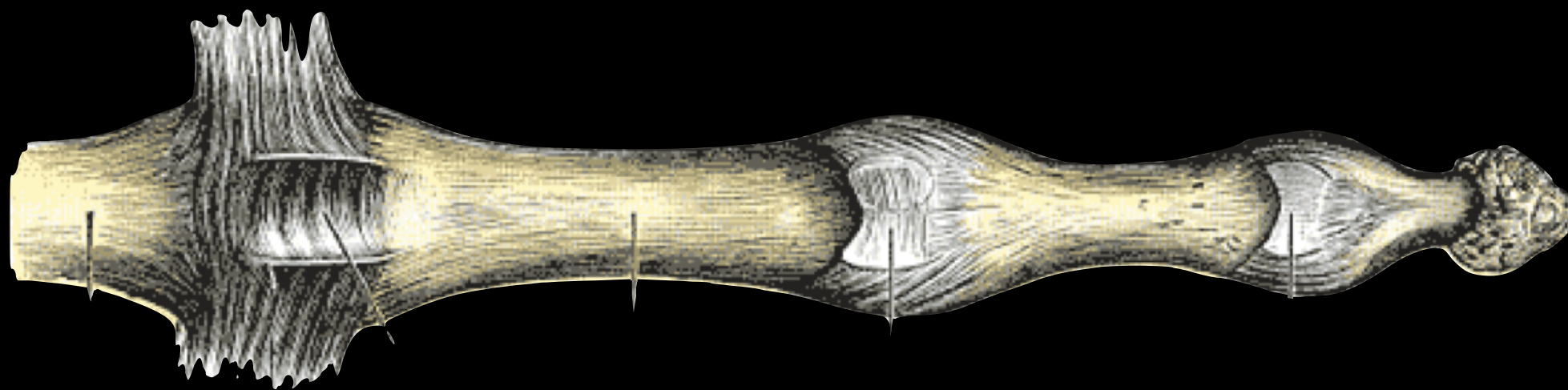
the volar plate



the volar plate



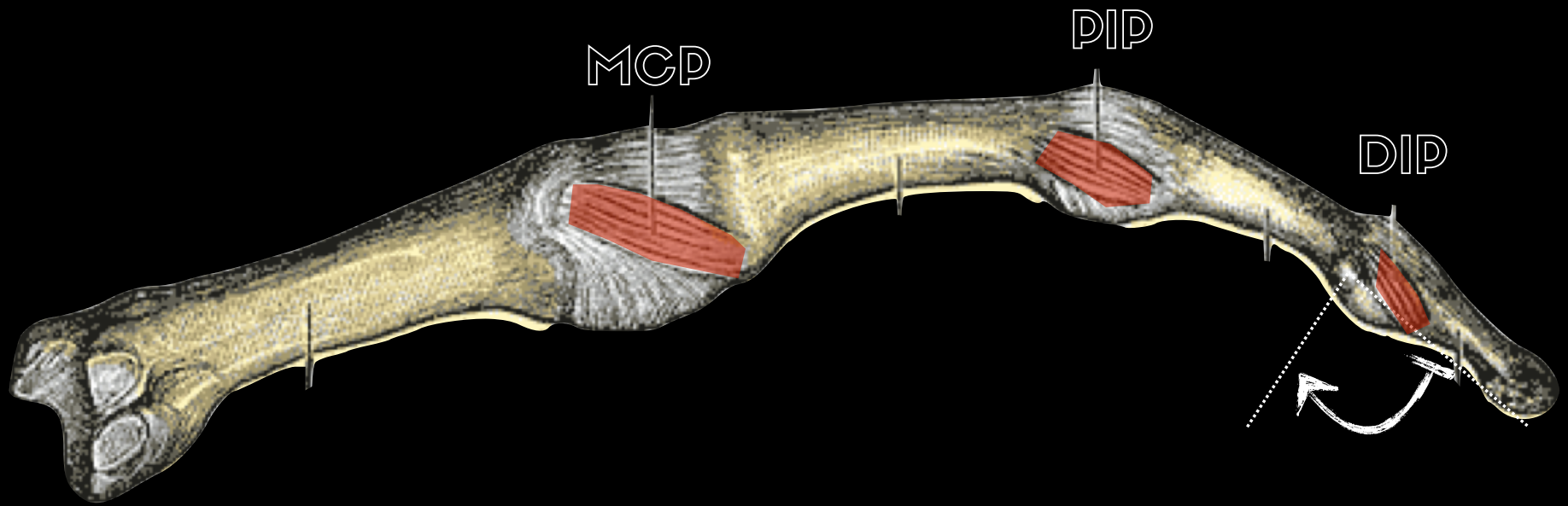
palmar ligament

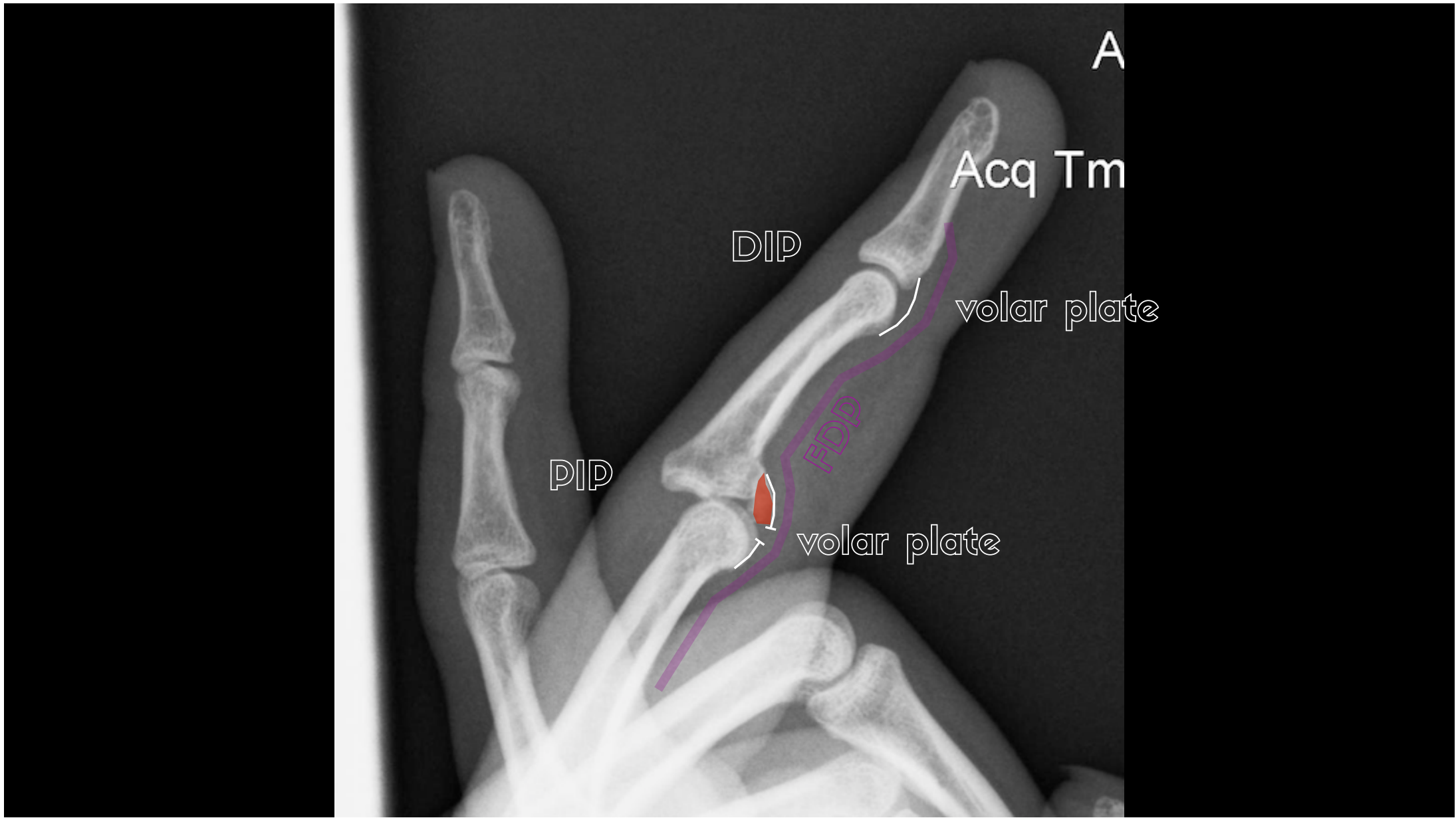

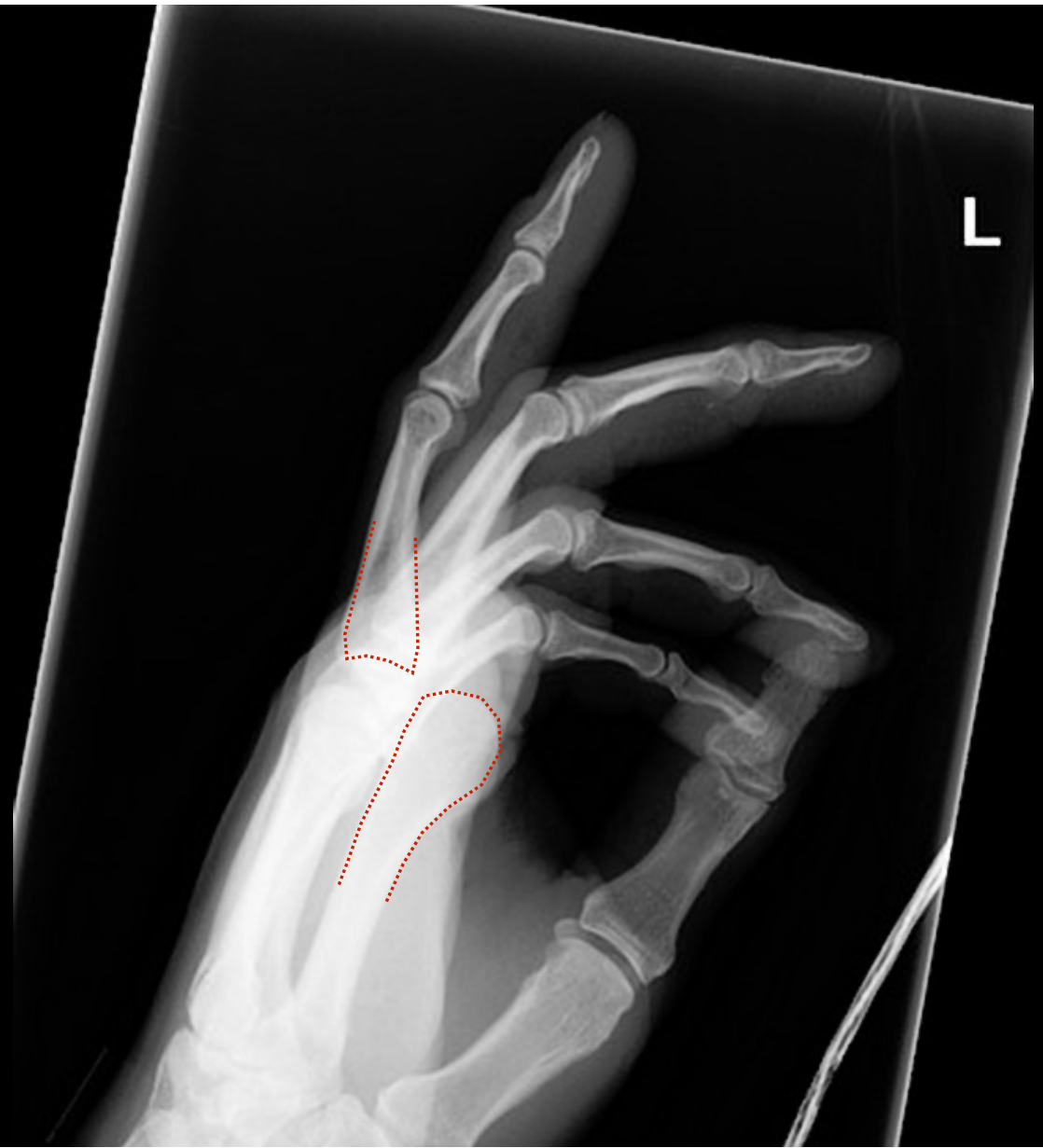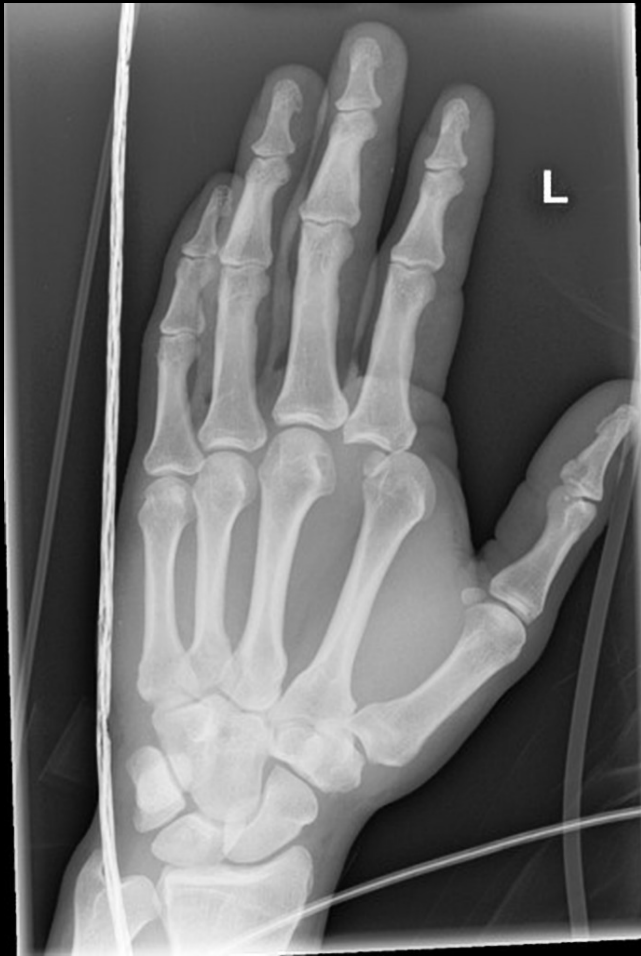MCP

DIP

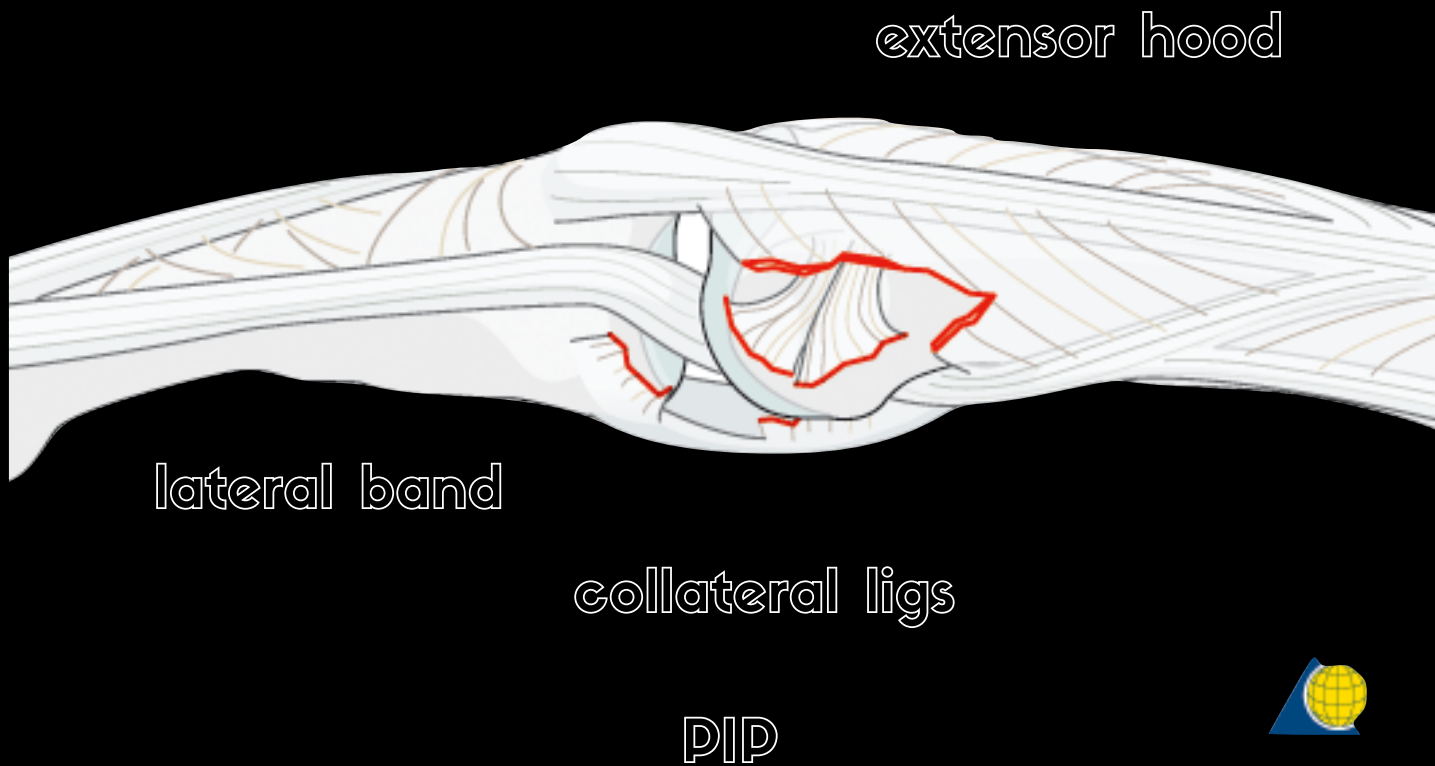
DIP







Case courtesy of Dr Henry Knipe,
Radiopaedia.org, rID: 40047



extensor hood

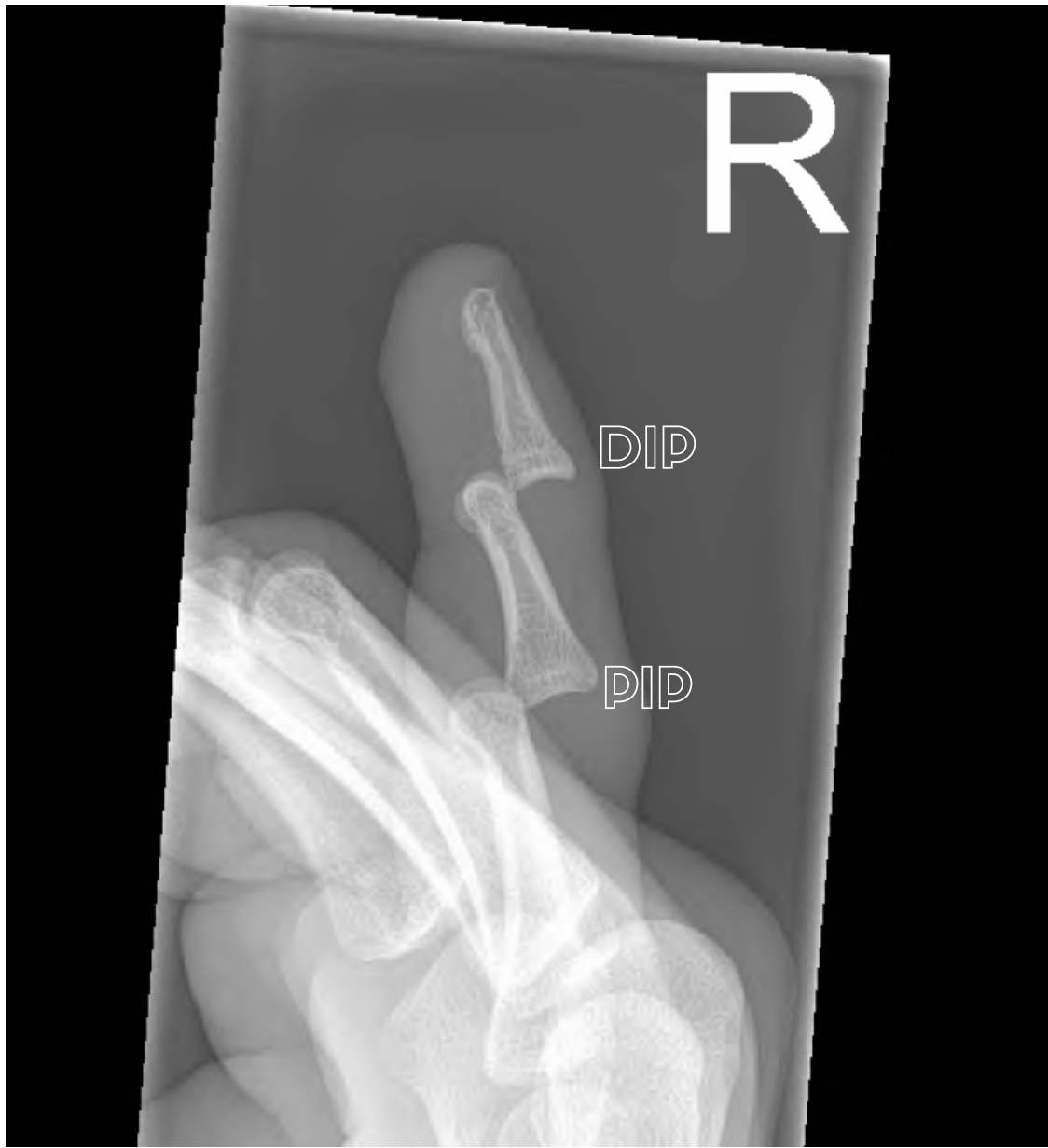lateral band

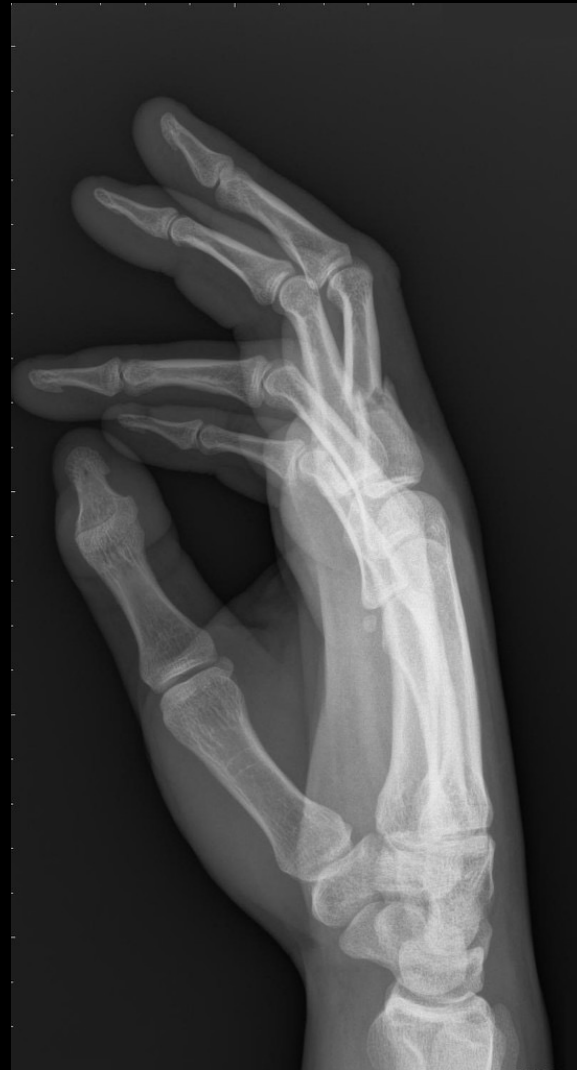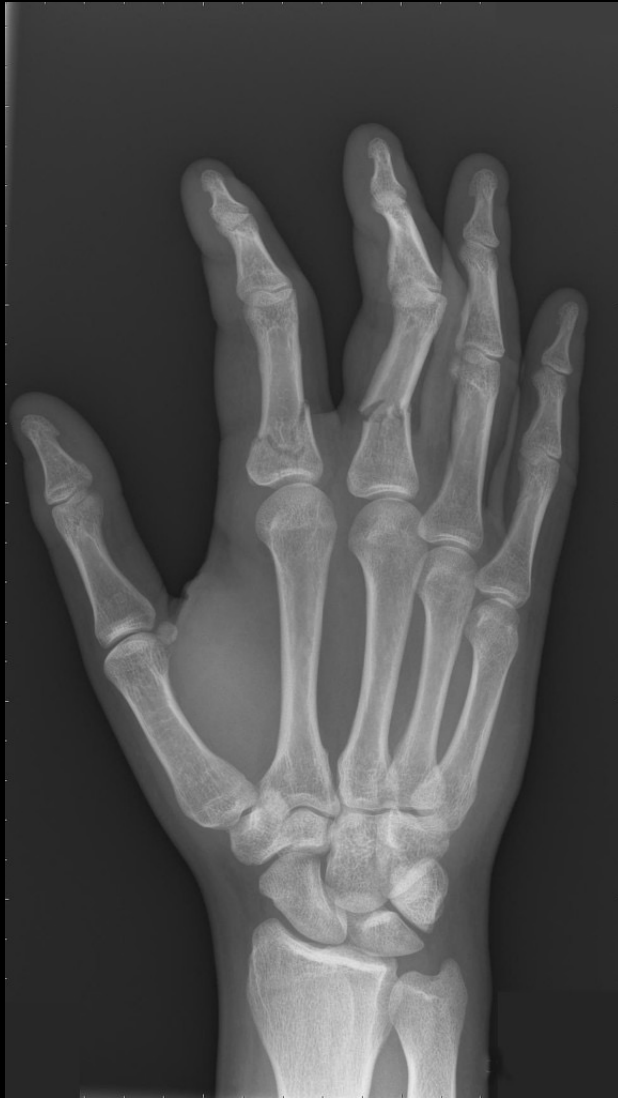collateral ligs

PIP



image credit <https://www2.aofoundation.org>





Case courtesy of Dr Tom O'Grady, Radiopaedia.org, rID: 41772

