



anatomy  
for

EMERGENCY MEDICINE

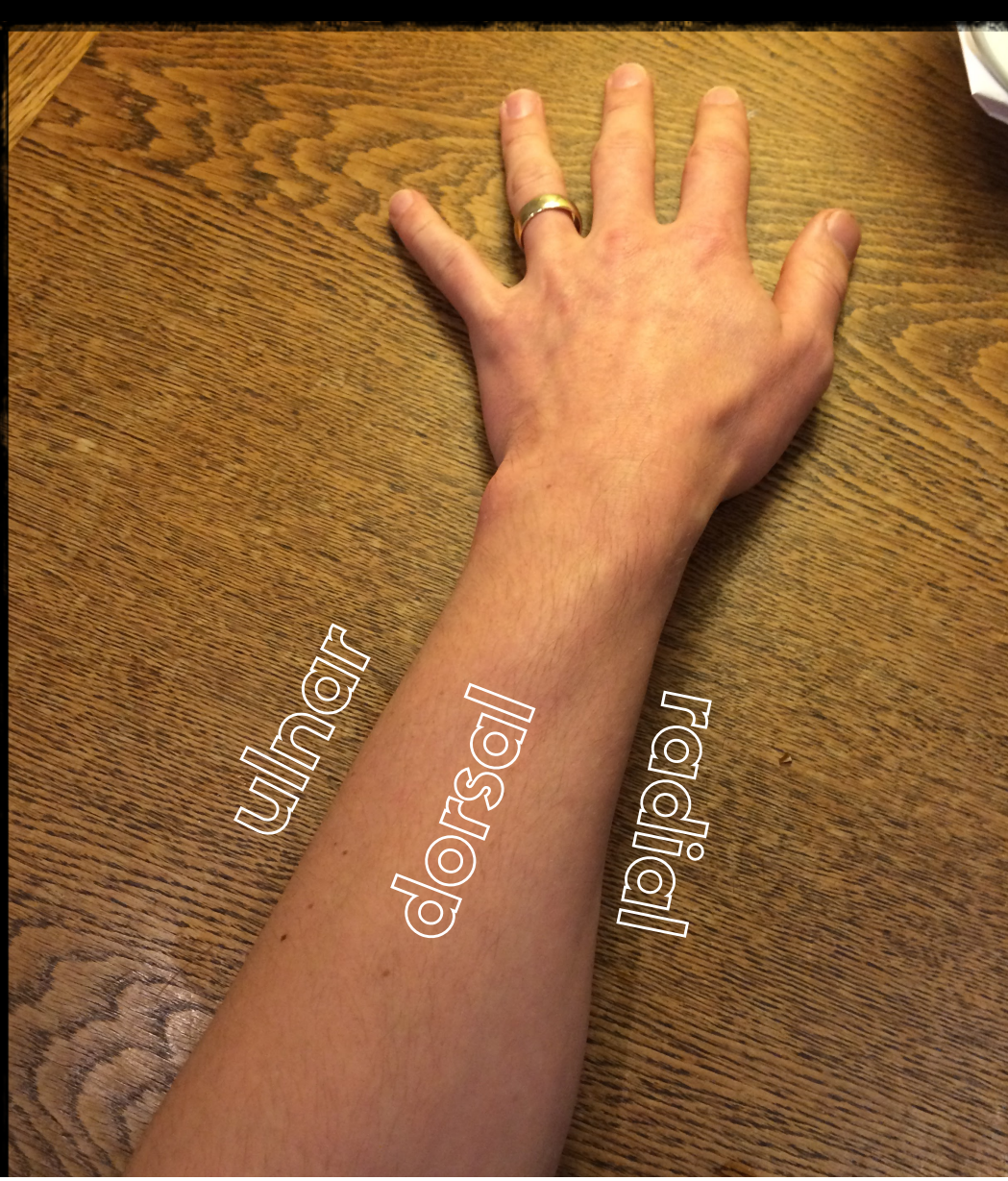

image: Mark Spearkman CC License <https://www.flickr.com/photos/mspearman/>





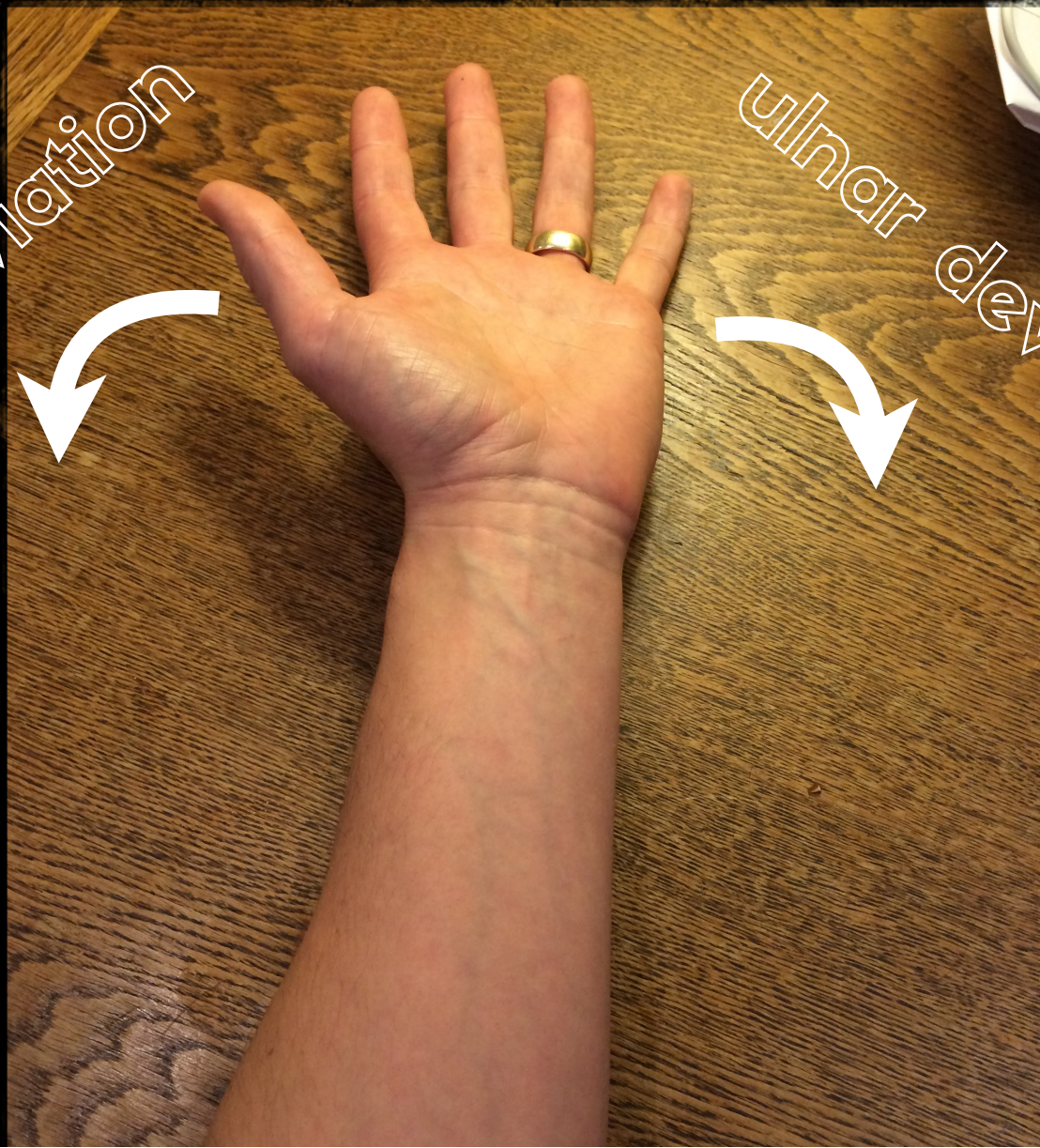know the lingo



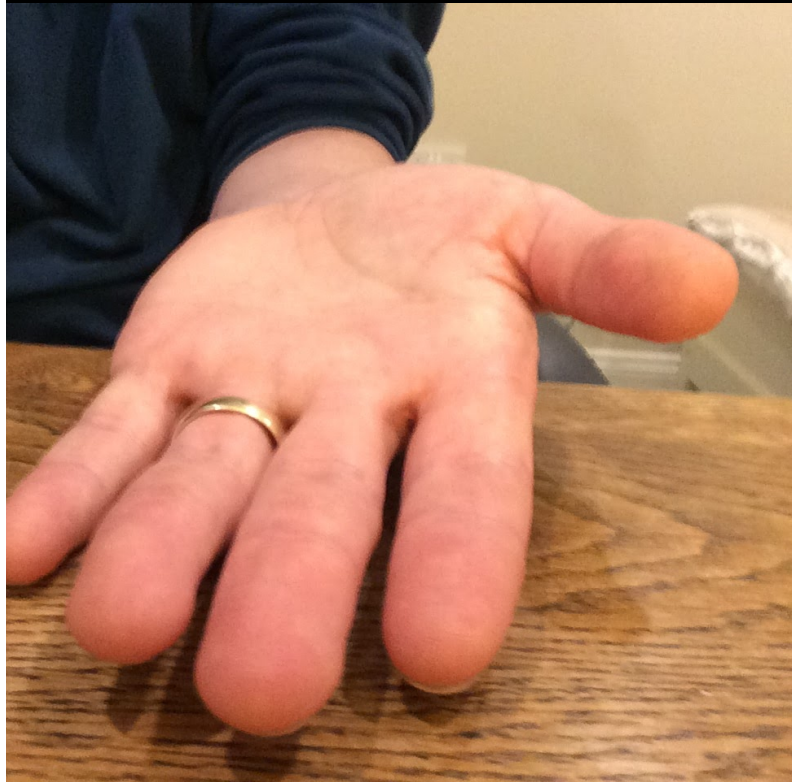radial deviation



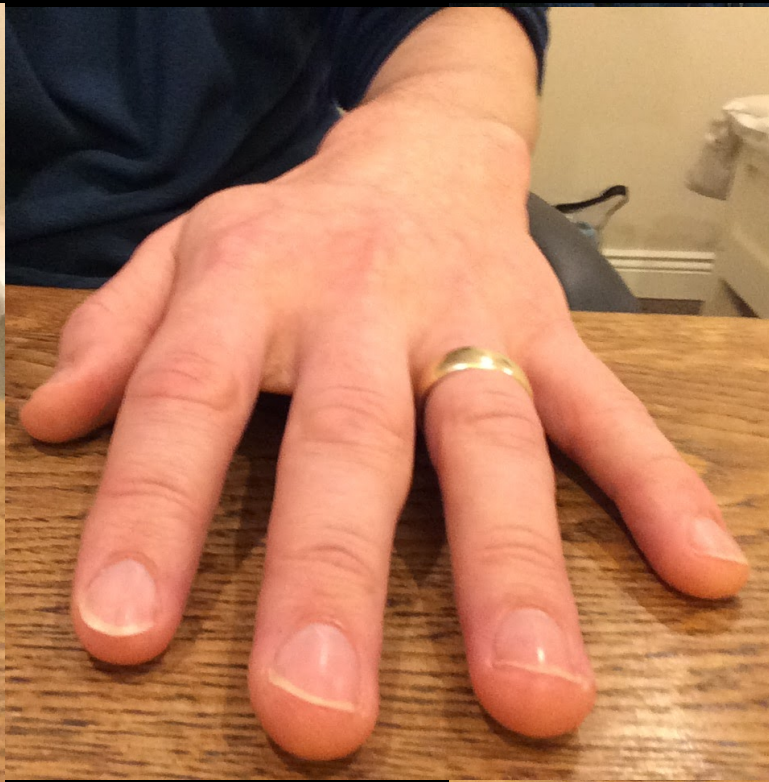ulnar deviation



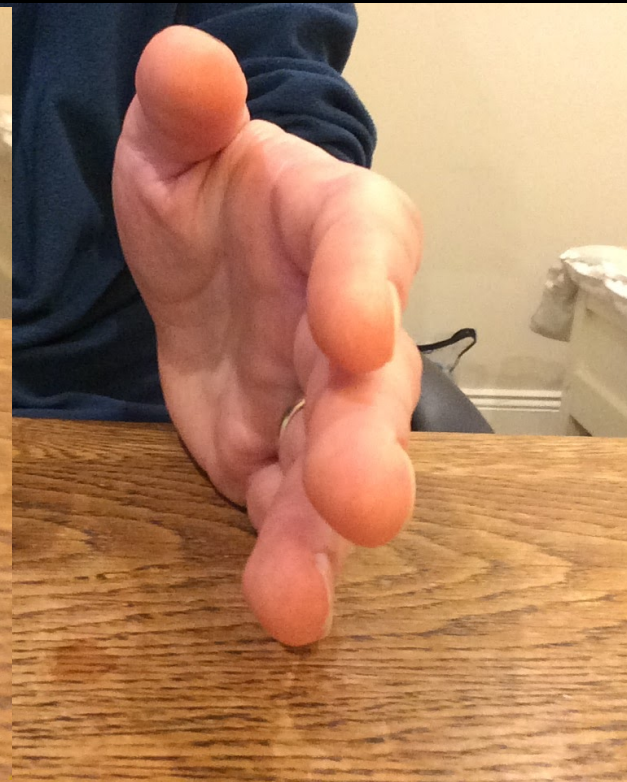
supination



pronation



“resting”







thumb

index

middle

ring

little



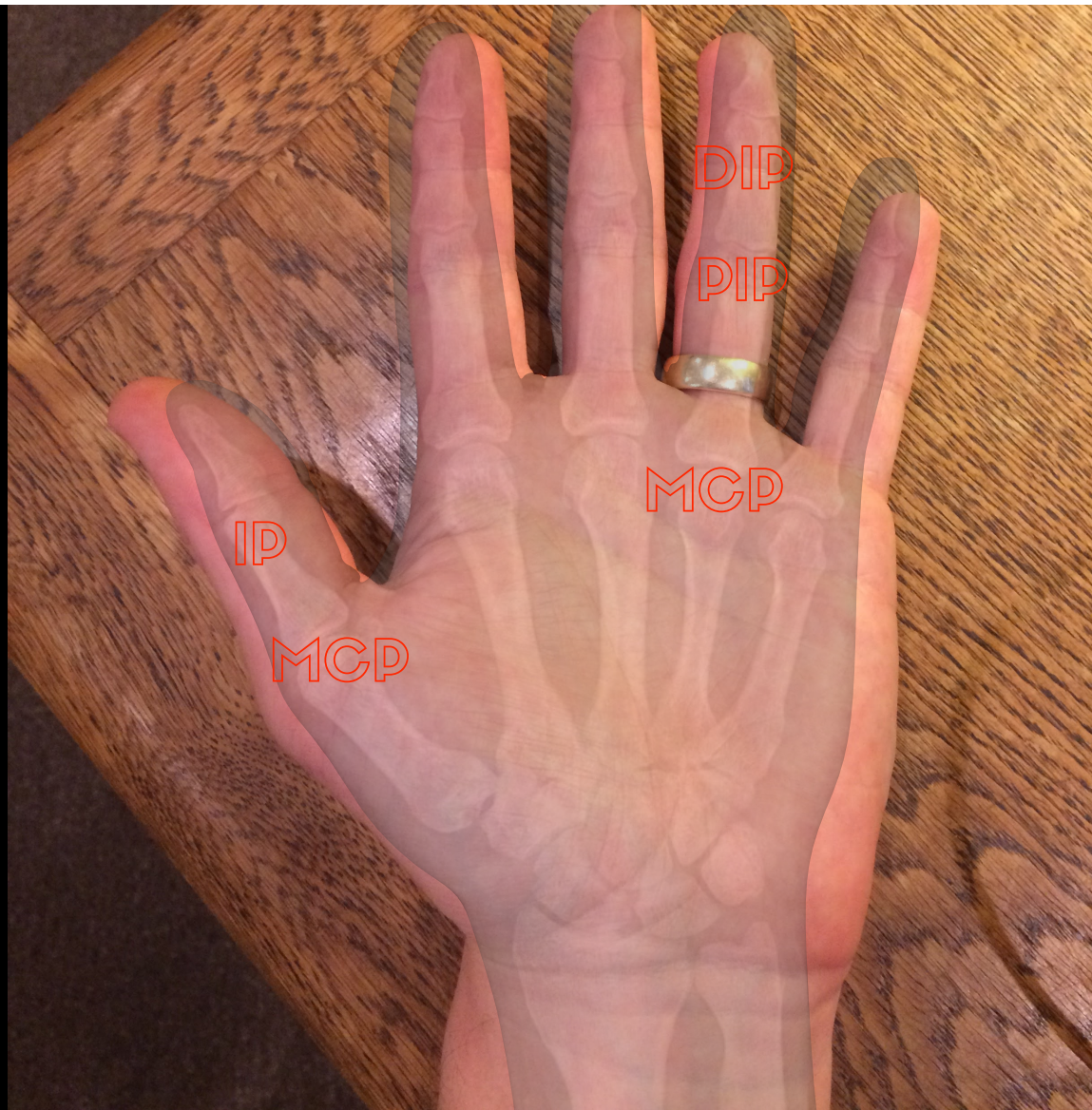MCP


IP

DIP

DIP

MCP





radial

index

PIP

volar

the soft tissues

muscles

tendons

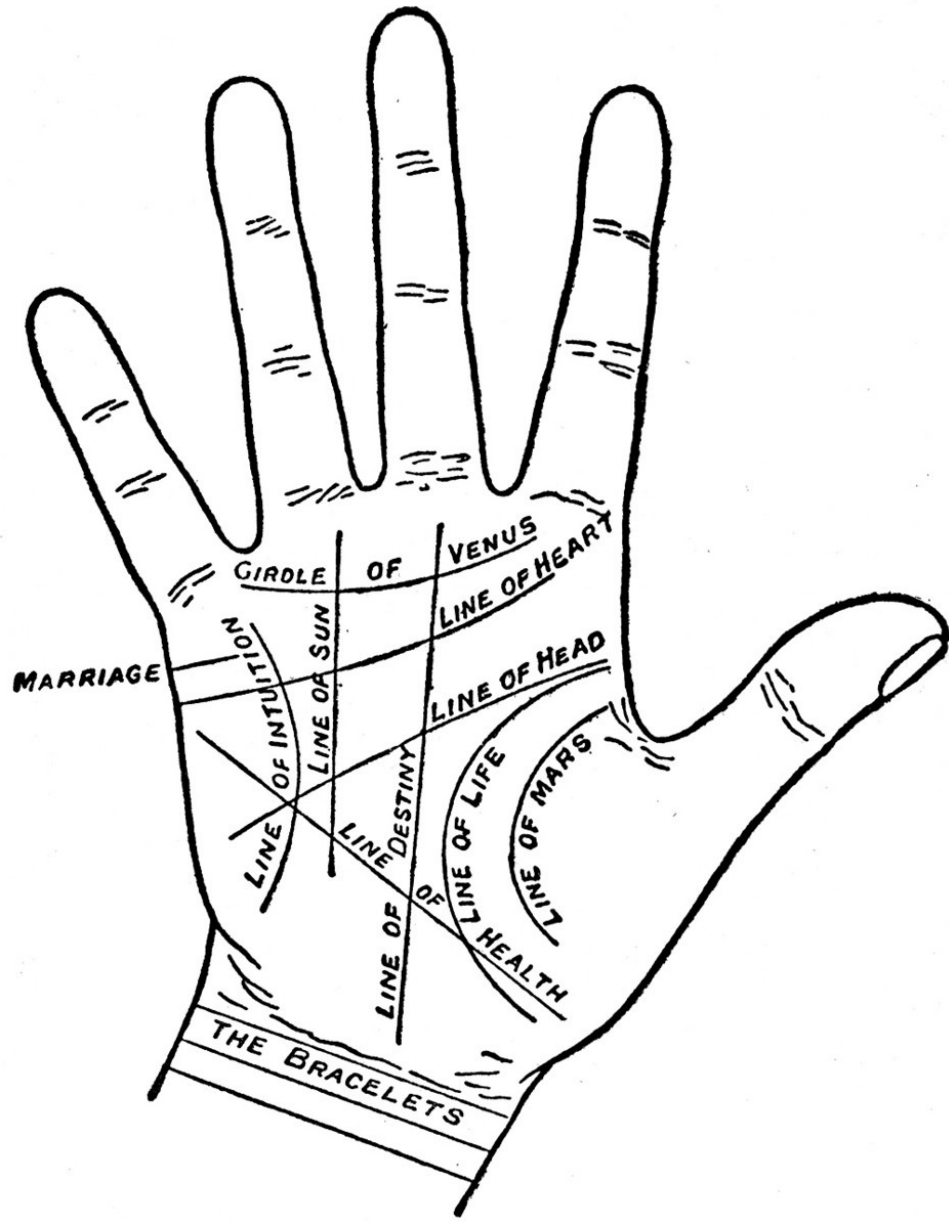
nerves

bones

vasculature

soft tissue

# palministry


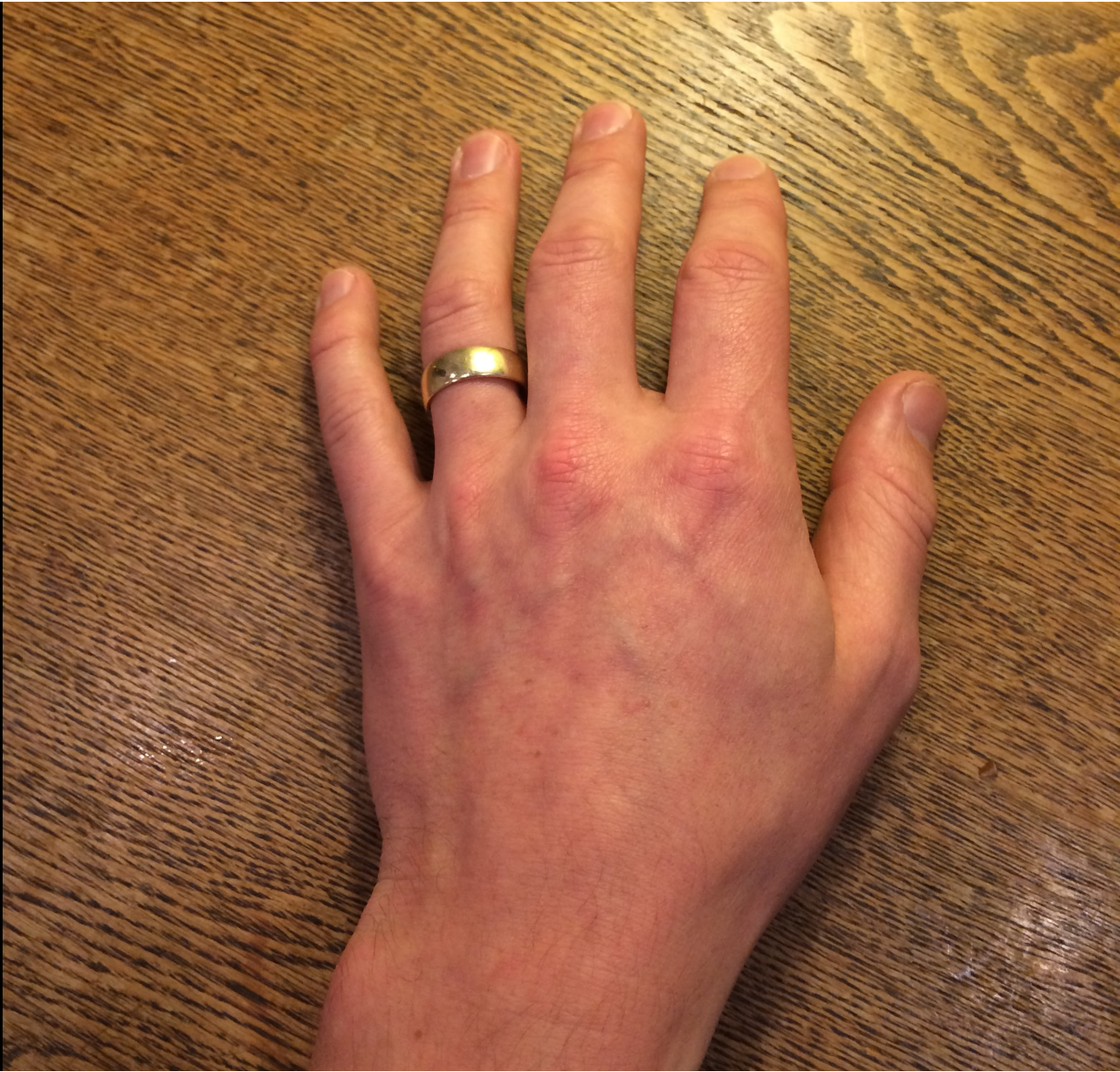


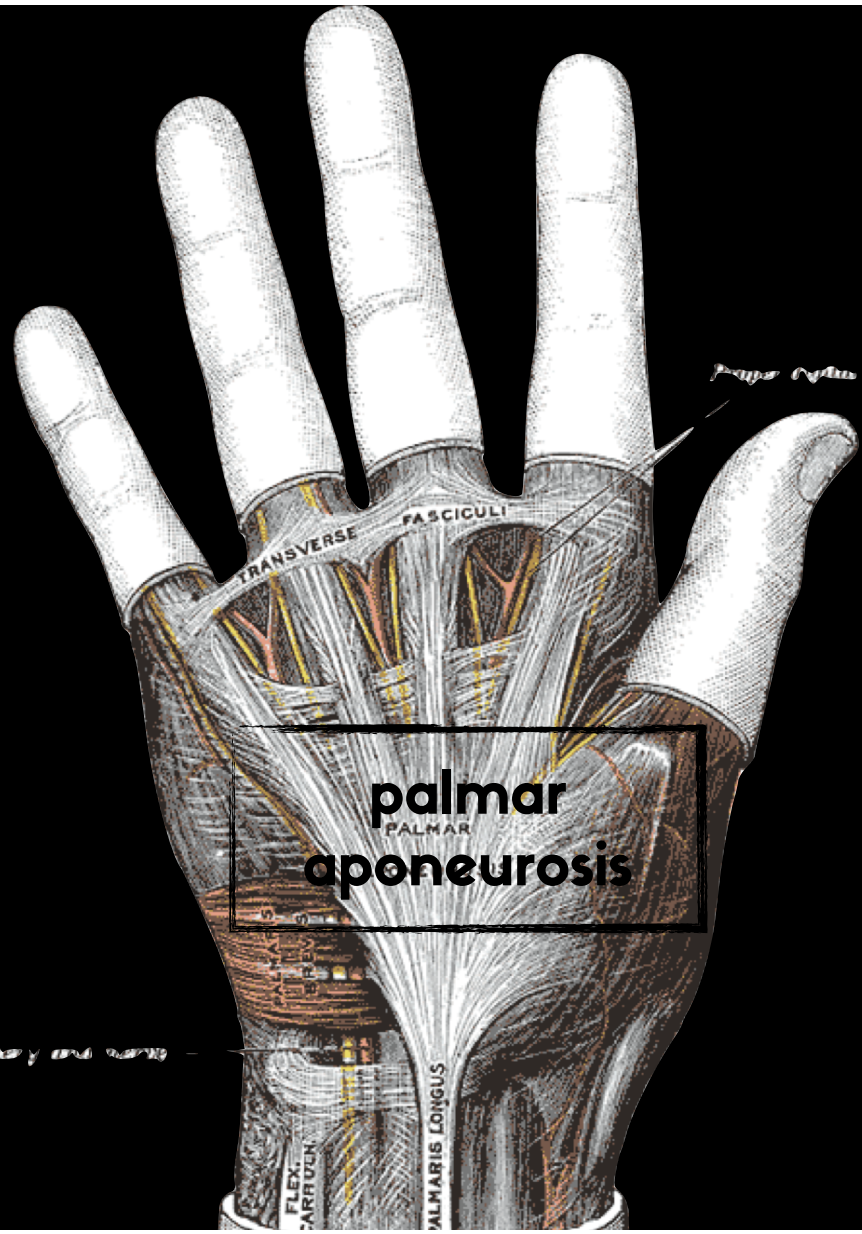




image credit: Journalist 2nd  
Class Alyssa Batarla.  
CC License. Wikipedia





**palmar**  
PALMAR  
**aponeurosis**

*Palmar aponeurosis every 1 cm wide*

*Flexor carpi ulnaris*

FLEX.  
CARPI ULN.

PALMARIS LONGUS

